




## REPORTS OF MORPHOLOGY

*Official Journal of the Scientific Society of Anatomists,  
Histologists, Embryologists and Topographic Anatomists  
of Ukraine*

journal homepage: <https://morphology-journal.com>



## Fetal ultrasound anatomy and morphometric parameters of the tibia

**Komar T. V., Khmara T. V., Protsak T. V., Zamorskii I. I., Kovalchuk P. Ye. Halaturnyk I. B.**

Bukovinian State Medical University, Chernivtsi, Ukraine

### ARTICLE INFO

Received: 22 January 2024

Accepted: 13 March 2024

UDC: 611.98-047.37-026.572.2

### CORRESPONDING AUTHOR

e-mail: [komar.tetiana.ls14@bsmu.edu.ua](mailto:komar.tetiana.ls14@bsmu.edu.ua)  
Komar T. V.

### CONFLICT OF INTEREST

The authors have no conflicts of interest to declare.

### FUNDING

Not applicable.

### DATA SHARING

Data are available upon reasonable request to corresponding author.

Ultrasound screening is one of the most informative methods of visualizing fetal development during pregnancy. During standard ultrasound examinations, the length of the femur of the fetus is measured. However, if any skeletal dysplasia or intrauterine growth retardation is suspected, additional measurement of other long tubular bones should be performed. The aim of the work was to investigate the morphometric parameters of the lengths of the right and left tibia bones and to establish correlations between them and the lengths of the corresponding fibula, lower limb and crown rump length of the fetus during the fetal period of human ontogenesis. Intravital ultrasound examination of the leg bones of 38 human fetuses was performed at the medical center "YUZKO MEDICAL CENTER" in accordance with the cooperation agreement. Built-in capabilities of MS Excel were used for statistical calculations. The established data on the fetal morphometry of tibial lengths indicate relatively uniform growth of the right and left tibias during the fetal period of human ontogenesis: the length of the right tibia increases from  $24.77 \pm 2.25$  mm to  $65.32 \pm 2.20$  mm, and the length of the left tibia increases from  $25.19 \pm 1.63$  mm to  $65.78 \pm 1.81$  mm. The analysis of correlations between the length of the right and left tibia bones, the length of the fibula bones, the length of the lower limbs and the crown rump length in human fetuses aged from 4 to 10 months of intrauterine development allowed to reveal reliable strong and medium strength reliable and unreliable, mostly direct, connections in all age groups. The obtained morphometric parameters of tibia bones in fetuses of different gestational periods are important additional dimensions of fetobiometry, which can be used if a detailed assessment of the state of fetal development is necessary and in case of suspicion of congenital anomalies.

**Keywords:** ultrasound diagnostics, tibia, morphometry, fetus, human.

### Introduction

Philippe Jeanty, MD, well-known in obstetrics and gynecology, made a significant contribution to the study of fetal ultrasound anatomy, biometry, diagnosis of congenital anomalies and for the first time traced the dynamics of fetal growth, described the growth of long tubular bones, as well as abdominal circumference and subsequently estimated the weight of the fetus. The scientist devoted his dissertation work to fetometry - the assessment of fetal growth by measuring the parameters of long tubular bones. At this very early stage in the development of ultrasound imaging, when ultrasound still only vaguely distinguished bones, Philippe Jeanty undertook a large-scale project to measure all the major long tubular bones (humerus, femur, ulna, radius, tibia and fibula) in a large number of fetuses and developed charts morphometric parameters of the long tubular bones of the fetus to determine the gestational age, which still do not lose their relevance [26].

Today, ultrasound screening remains one of the most

informative methods of visualizing the normal development of the fetus during certain periods of pregnancy. This method allows not only to assess the general condition of the fetus, but also to determine the morphometric parameters of organs and structures, which is important for timely diagnosis of any birth defects or anomalies [1, 20].

Measurement of the length of the long tubular bones of the fetus is used to analyze the fetal anatomy and estimate the gestational age. In addition, this parameter is key for the early detection of chromosomal abnormalities and osteochondrodysplasias [7, 12, 27]. In conventional ultrasound examinations, the length of the femur of the fetus is usually measured, but in case of suspicion of any skeletal dysplasia or intrauterine growth retardation, it is necessary to additionally measure other long tubular bones for a more detailed assessment of the condition of the fetus.

Triple screening ultrasound examination of pregnant women makes it possible to detect anomalies and

deviations in the development of the fetus. Researchers are interested in the intermediate period of the ontogenesis of the fetus, which corresponds to the period of development from 16 to 28 weeks of the intrauterine period. It is at this time that all organs and systems of the fetus are actively forming, coinciding with the second standard ultrasound screening. Despite certain difficulties of ultrasound diagnostics, its effectiveness in detecting fatal skeletal anomalies ranges from 94 % to 96 %. Abnormalities of the lower extremity in general, such as campomelia, sirenomelia, and phocomelia, are rarely found in the literature. Instead, congenital malformations of the tibia or fibula, such as hemimelia, hypoplasia, congenital false joint, or congenital curvature, are more commonly noted. Most often, congenital malformations and anomalies of the shin bones are unilateral (31 %) [3, 8, 13, 23].

Modern international standards of fetal growth rate are presented in the INTERGROWTH-21 program, which was developed for comprehensive monitoring of normal fetal development around the world. Curves of the growth rate of the fetus help to understand the normogenesis of the fetus and the occurrence of pathological changes in its development. It is ultrasound diagnostics that allows you to visualize all planes of the fetus, which are necessary for accurate biometric measurements. The fetal growth profile includes 12 biometric parameters: biparietal diameter, occipital-frontal diameter, head circumference, transverse and sagittal diameters of the abdomen, abdominal circumference, lengths of the femur, tibia, fibula, humerus, radius, and ulna [13, 21]. Measurement of the length of the long tubular bones is also used to determine the age and time of death of the fetus in case of its intrauterine death [14].

At present, it is the combination of imaging parameters obtained with the help of ultrasound diagnostics, computer and magnetic resonance imaging that allows not only to detect congenital malformations, but also to predict mortality before the birth of a child [4, 11, 19]. Possible applications of these measurements include: intrauterine diagnosis of fetal growth retardation [6], congenital malformations of limbs, determination of gestational age, archaeological dating of fetuses, forensic research [9, 20], introduction of ultrasound modeling in medical education [12]. Our study of the morphometric parameters of the lower leg bones during the fetal period of human ontogenesis is a continuation of our own research.

*The aim of the work* was to investigate the morphometric parameters of the lengths of the right and left tibia bones and to establish correlations between them and the lengths of the corresponding fibula, lower limb and crown rump length of the fetus during the fetal period of human ontogenesis.

### Materials and methods

Intravital ultrasound examination of the shin bones of 38 human fetuses was performed using a 3.5 MHz convex sensor on a Voluson E8 ultrasound scanner (manufactured

by General Electric, 2013) in the medical center "YUZZO MEDICAL CENTER" in accordance with the cooperation agreement. Measurements were performed according to standardized protocols by an experienced sonologist. The length of the tibia was determined by measuring the distance between the extreme points of the proximal and distal epiphyses. Lateral and medial cuneiform bones, which are used as reference points for measurement in adults, have not yet been determined in fetuses of this age. The tibia was measured in a plane so that the latter was as close as possible to the angle of passage of the ultrasound beam so that the full length of the bone was visualized and was not obscured by the shadow of the adjacent bone parts. If any abnormality was detected in the fetus during the ultrasound diagnosis, the fetus was not included in the sample. The study was conducted in accordance with the main bioethical provisions of the Council of Europe Convention on Human Rights and Biomedicine (from 04.04.1997), the Helsinki Declaration of the World Medical Association on the ethical principles of conducting scientific medical research with human participation (1964-2013), order of the Ministry of Health of Ukraine № 690 dated 23.09.2009, the Commission on Biomedical Ethics of the Bukovinian State Medical University (Protocol № 3 dated 16.11.2023) did not detect any violations of moral and legal norms during the conduct of research work.

The built-in features of MS Excel were used to perform statistical calculations, including the calculation of the arithmetic mean and standard deviation. Comparison between study groups was performed using the non-parametric Mann-Whitney test, which was performed in the Excel environment. The level of significance of individual indicators relative to the corresponding ones in different age periods of human fetal development is determined. In addition, the Pearson correlation coefficient was determined between the morphometric indicators of the length of the tibia and the lengths of the fibula, lower limb and crown rump length in human fetuses of 4-10 months.

### Results

As a result of the research, morphometric characteristics of the length of the right and left tibia bones in human fetuses of 4-10 months were established (Table 1).

Measurements of the length of the tibia of fetuses of the indicated age showed that the length of the right tibia increased by 2.64 times, from  $24.77 \pm 2.25$  mm to  $65.32 \pm 2.20$  mm, and the length of the left tibia increased by 2.61 times, from  $25.19 \pm 1.63$  mm to  $65.78 \pm 1.81$  mm (Fig. 1-8, see Table 1).

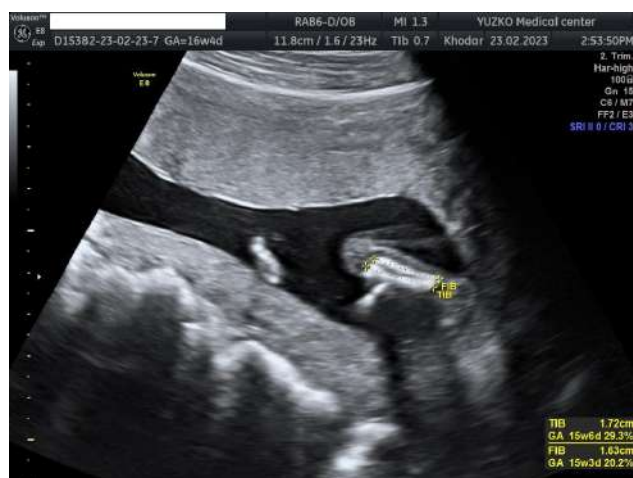During the analysis of the obtained data, two active periods of tibial bone growth were revealed: from the end of the 5th to the end of the 6th month of intrauterine development and during the 7th month of the fetal period of development. At the same time, a slowdown in the growth of the right and left tibia bones is observed in the 4th and 10th months of intrauterine development (Fig. 9).

In the period of human fetal development, the length of

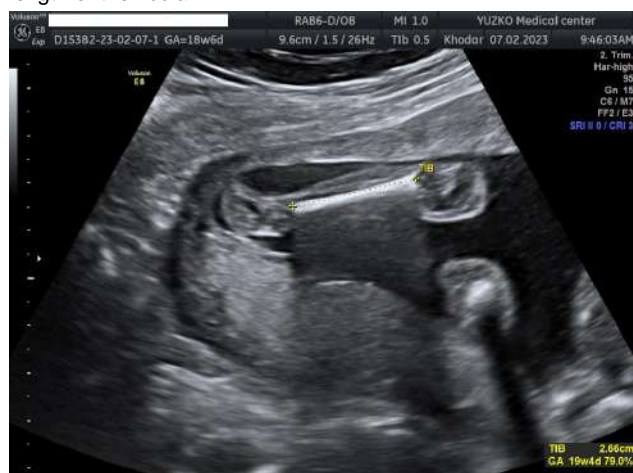**Table 1.** The length of tibia bones in human fetuses aged 4-10 months ( $M \pm \sigma$ ).

Gestation period	Number of fetuses (n)	Length of tibia (mm)	
		right	left
4 months	6	24.77±2.25	25.19±1.63
5 months	6	30.78±2.27*	31.04±2.16*
6 months	6	39.96±2.07*	40.82±1.91*
7 months	6	47.27±1.49*	48.56±1.32*
8 months	5	54.05±1.41*	54.93±1.01*
9 months	5	60.48±1.72*	61.13±1.46*
10 months	4	65.32±2.20*	65.78±1.81*

**Notes:** \* - the level of significance between individual indicators relative to the previous month of gestation ( $p < 0.05$ ).



**Fig. 1.** Sonogram of the tibia and fibula bones of a human fetus at 16 weeks and 4 days of gestation. TIB - length of the tibia; FIB - length of the fibula.

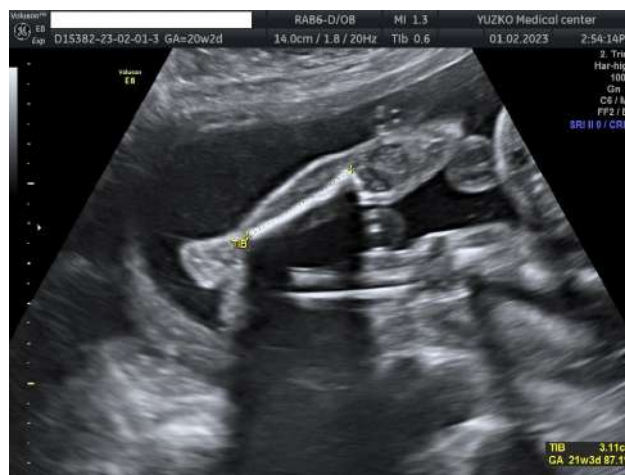

**Fig. 2.** Sonogram of the tibia of a human fetus at 18 weeks 6 days of gestation. TIB - length of the tibia.

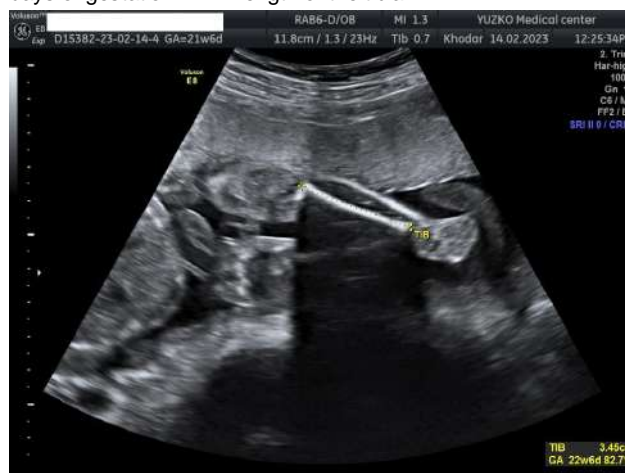the right lower limb increases from  $44.87 \pm 3.33$  mm to  $192.1 \pm 5.7$  mm, and the length of the left lower limb increases from  $44.45 \pm 3.19$  mm to  $194.1 \pm 5.9$  mm (Table 2).

During the analysis of correlations between the length of the right and left tibia bones in human fetuses aged from 4

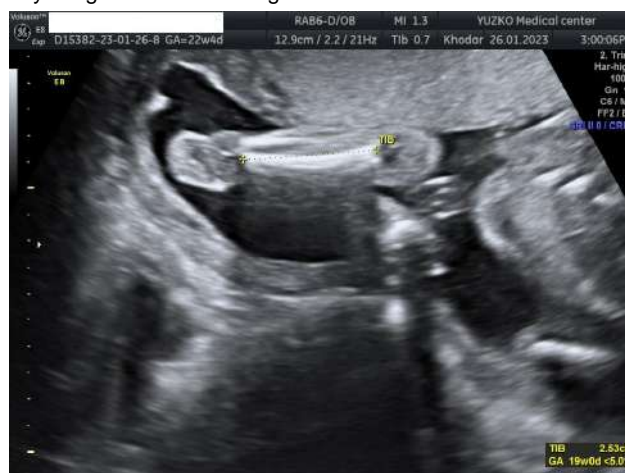to 10 months of intrauterine development, reliable strong direct correlations were found in all age groups ( $r =$  from 0.71 to 0.89). Between the length of the right tibia and the right fibula in 4-month-old fetuses, a reliable strong direct



**Fig. 3.** Sonogram of the tibia of a human fetus at 20 weeks and 2 days of gestation. TIB - length of the tibia.

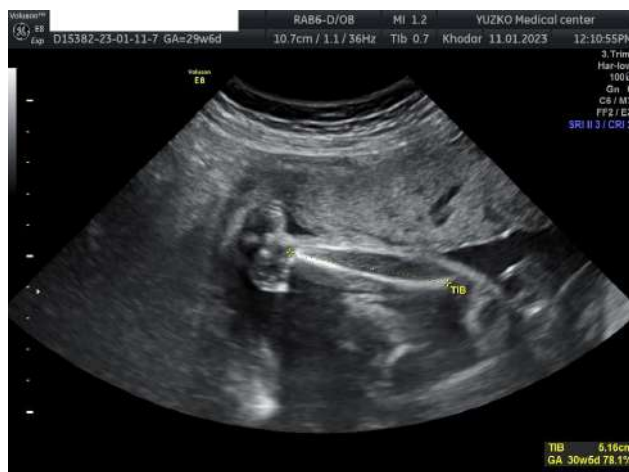

**Fig. 4.** Sonogram of the tibia of a human fetus at 21 weeks and 6 days of gestation. TIB - length of the tibia.

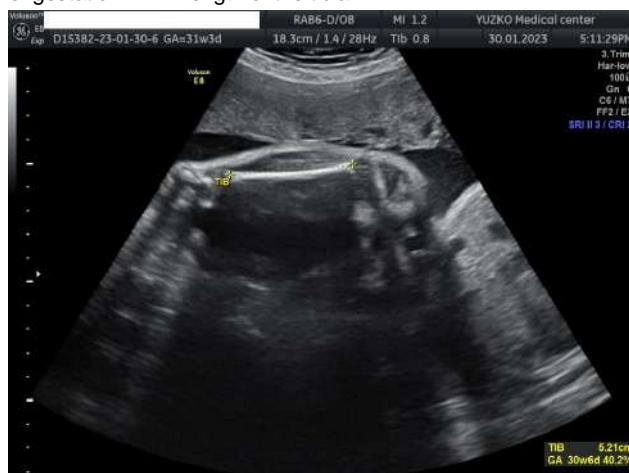

**Fig. 5.** Sonogram of the tibia of a human fetus at 22 weeks and 4 days of gestation. TIB - length of the tibia.

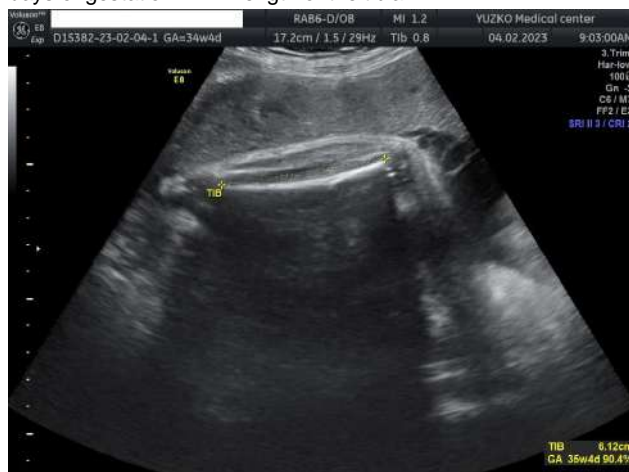



**Fig. 6.** Sonogram of the tibia of a human fetus at 29 weeks 6 days of gestation. TIB - length of the tibia.



**Fig. 7.** Sonogram of the tibia of a human fetus at 31 weeks 3 days of gestation. TIB - length of the tibia.



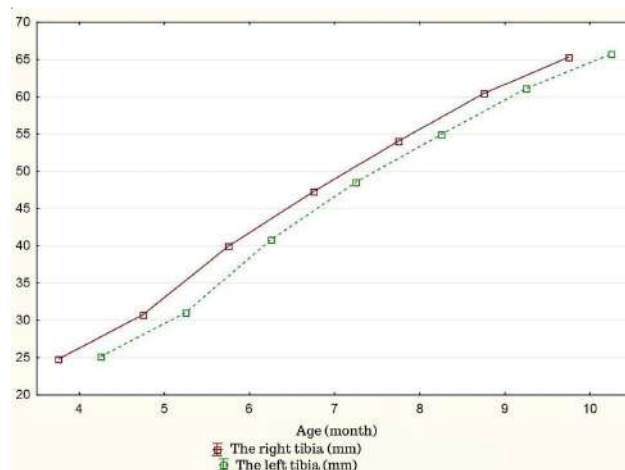
**Fig. 8.** Sonogram of the tibia of a human fetus at 34 weeks 4 days of gestation. TIB - length of the tibia.

correlation was established ( $r=0.97$ ), in 7-month-old fetuses there was an unreliable inverse correlation of medium strength ( $r=-0.38$ ), in all other age groups - reliable and unreliable direct correlations of average strength ( $r=$  from

0.32 to 0.62). When analyzing correlations between the length of the right tibia and the length of the right lower limb, unreliable weak direct correlations were found in fetuses of 5, 8 and 10 months ( $r=$  from 0.10 to 0.21), unreliable and reliable direct correlations of medium strength in fetuses 4 and 9 months ( $r=0.36$  and 0.50), in 6-month-old fetuses - reliable medium strength inverse correlations ( $r=-0.57$ ). In fetuses of 7 months, correlations between the length of the right tibia and the length of the right lower limb are absent.

During the assessment of correlations between the length of the right tibia and crown rump length, the following was found: unreliable weak direct correlations in fetuses of almost all age groups ( $r=$  from 0.10 to 0.29), with the exception of fetuses of 8 and 9 months of age, in which unreliable average direct correlations ( $r=0.31$  and 0.32).

According to the results of the study of the correlation dependence between the length of the left tibia and the length of the left lower limb, reliable and unreliable direct correlations of average strength were found in fetuses of 8-10 months ( $r=$  from 0.39 to 0.59), reliable inverse correlations of average strength in fetuses of 6 months of age ( $r=-0.57$ ). In fetuses of 5 months, unreliable weak direct correlations ( $r=0.28$ ) were established, and in fetuses of 4 and 7 months,



**Fig. 9.** Dynamics of changes in the length of tibia bones in fetuses aged 4-10 months.

**Table 2.** The length of the lower limbs in human fetuses aged 4-10 months ( $M \pm \sigma$ ).

Gestation period	Number of fetuses (n)	Length of the lower limb (mm)	
		right	left
4 months	20	44.87±3.33	44.45±3.19
5 months	21	73.55±6.56*	74.06±6.51*
6 months	19	100.2±2.9*	99.40±2.65*
7 months	15	126.9±2.7*	124.4±3.5*
8 months	10	141.1±1.3*	141.8±1.4*
9 months	8	161.1±2.7*	161.5±3.9
10 months	9	192.1±5.7*	194.1±5.9*

**Notes:** \* - the level of significance between individual indicators relative to the previous month of gestation ( $p < 0.05$ ).

correlations between the length of the left tibia and the length of the left lower limb were not observed.

Evaluating the correlations between the length of the left tibia and the length of the left fibula, the following was established: strong reliable direct correlations in fetuses of 4 months of age ( $r=0.97$ ), reliable and unreliable direct correlations of medium strength in fetuses of 5, 6, 8 and 9 months ( $r=$  from 0.44 to 0.66), unreliable weak direct correlations in fetuses of 10 months ( $r=0.25$ ).

In fetuses of 7 months, correlations between the length of the left tibia and the length of the left fibula were not observed. During the analysis of correlations between the length of the left tibia and crown rump length, we found the following: in fetuses aged from 7 to 10 months of intrauterine development, reliable and unreliable direct correlations of medium strength are observed ( $r=$  from 0.40 to 0.54), in 4- and 5-month-old fetuses - unreliable weak direct correlations ( $r=0.13$  and 0.19), and in 6-month-old fetuses, reliably strong inverse correlations ( $r=-0.98$ ) were established.

### Discussion

Thus, the conducted morphometric study made it possible to evaluate the correlations between the lengths of the right and left tibia bones, right and left fibula bones and lower limbs in human fetuses of 4-10 months, as well as fetuses crown rump length. Two periods of intensive growth of the length of the right and left tibia bones were established, namely: from the end of the 5th month to the end of the 6th month of intrauterine development and during the 7th month of the fetal period of human ontogenesis. The periods of slow growth of the tibia are the 4th and 10th months of gestation.

Undoubtedly, an integral part of prenatal examination is ultrasound diagnostics, which is highly informative and safe, and every year not only the technical capabilities of ultrasound machines, but also the system for assessing the development of the fetus are improved. R. Yousefpour Shahrivar et al. [28] emphasize the need for further research in this field, which will contribute to more effective detection of fetal abnormalities based on ultrasound.

Our study confirms the opinion of some authors [2, 11], who claim that ultrasound measurement of the bones of the lower leg is simpler than that of the forearm. This is because the tibia and fibula are similar in size and location, making them easier to visualize with ultrasound. Despite the difficulty of accurate diagnosis, the frequency of detection of fatal anomalies of the skeleton using ultrasound is 94-96%. Even if an anomaly of the musculoskeletal system is diagnosed, not all prenatal diagnostics are complete, in some cases additional examination is required after childbirth [13, 22]. Although ultrasonography plays almost the most important role in detecting skeletal abnormalities [17, 25], some authors believe that genetic tests at the molecular level should be used to confirm chromosomal mutations and improve the accuracy of prenatal diagnosis [16].

In the sources of literature [10, 12] we find data that most often congenital malformations and anomalies of tibia bones are unilateral, however, we did not detect differences in the growth of the right and left tibia bones, changes in their structure and developmental anomalies in the examined fetuses.

The periods of intensive growth of the lengths of the right and left tibia bones that we established are partially consistent with existing data [1, 14]. However, we did not have information about the peculiarities of the course of pregnancy, the presence of concomitant diseases of the mother, or the peculiarities of her diet.

Graphs of changes in the length of long tubular bones are widely used in clinical practice to track the growth of children. They were developed on the basis of detailed studies of normal bone development of different age groups. In 2006, the World Health Organization published the child development standards of the World Health Organization, which were widely used in practice [15]. However, some researchers even today question their use, because they do not take into account the characteristics of different populations and emphasize the need to have local standards of fetal biometrics [24, 30].

Plots of CT measurements against published sonographic values for age also showed strong and significant correlations, suggesting that the data can be used interchangeably [29].

Fetal growth retardation often complicates the course of the antenatal and postnatal periods, but currently there is no definitive treatment other than delivery. It is believed that the development of unified international protocols for the early recognition, follow-up and optimal management of fetuses with growth retardation will be able to improve the perinatal outcomes of such pregnancies [10]. Growth assessment protocols can potentially help prevent stillbirth, which is often associated with fetal growth retardation [5]. Existing studies during intrauterine development indicate the absence of significant gender differences in the length and structure of the tibia. However, gender differences in the ratio of femur to tibia were determined in adults ( $p<0.05$ ) [18].

### Conclusions

1. There were no significant differences in the length of the right and left tibia bones during the fetal period of human ontogenesis, and therefore the right and left tibia bones grow evenly.

2. It was established that an intensive increase in the length of the right and left tibia bones is observed from the end of the 5th to the end of the 6th month and during the 7th month of intrauterine development. The periods of slow increase in their length are the 4th and 10th months of intrauterine development.

3. Between the length of the right and left tibia bones, the length of the fibula bones, the lower limbs and the crown rump length in human fetuses of different gestational periods, multiple reliable and unreliable, mostly direct, medium-strength relationships were established.

## References

- [1] Aggarwal, N., & Sharma, G. L. (2020). Fetal ultrasound parameters: Reference values for a local perspective. *The Indian Journal of Radiology & Imaging*, 30(2), 149-155. doi: 10.4103/ijri.IJRI\_287\_19
- [2] Baschat, A. A. (2018). Planning management and delivery of the growth-restricted fetus. *Best Pract Res Clin Obstet Gynaecol*, 49, 53-65. doi: 10.1016/j.bpobgyn.2018.02.009
- [3] Basso, M., Camurri, V., Frediani, P., & Boero, S. (2018). A rare case of tibial hemimelia, surgical technique and clinical results. *Acta Orthop Traumatol Turc*, 52(4), 315-319. doi: 10.1016/j.aott.2017.11.004
- [4] Broere-Brown, Z. A., Schalekamp-Timmermans, S., Jaddoe, V. W. V., & Steegers, E. A. P. (2019). Deceleration of fetal growth rate as alternative predictor for childhood outcomes: a birth cohort study. *BMC Pregnancy Childbirth*, 19(1), 216. doi: 10.1186/s12884-019-2358-8
- [5] Butler, E., Hugh, O., & Gardosi, J. (2022). Evaluating the Growth Assessment Protocol for stillbirth prevention: progress and challenges. *Journal of Perinatal Medicine*, 50(6), 737-747. doi: 10.1515/jpm-2022-0209
- [6] Cupello, A. J., Ambrosio, J. D., & de Vasconcellos, H. A. (1995). Growth of the tibia and fibula bones in human fetuses. *Bulletin de l'Association Des Anatomistes*, 79(246), 17-20. PMID: 8541605
- [7] Deguchi, M., Tsuji, S., Katsura, D., Kasahara, K., Kimura, F., & Murakami, T. (2021). Current Overview of Osteogenesis Imperfecta. *Medicina (Kaunas)*, 57(5), 464. doi: 10.3390/medicina57050464
- [8] Dobbe, A. M., & Gibbons, P. J. (2017). Common paediatric conditions of the lower limb. *J Paediatr Child Health*, 53(11), 1077-1085. doi: 10.1111/jpc.13756
- [9] Fewtrell, M. S., Loh, K. L., Chomtho, S., Kennedy, K., Hawdon, J., & Khakoo, A. (2008). Quantitative ultrasound (QUS): a useful tool for monitoring bone health in preterm infants? *Acta Paediatr*, 97(12), 1625-1630. doi: 10.1111/j.1651-2227.2008.00992.x
- [10] Giouleka, S., Tsakiridis, I., Mamopoulos, A., Kalogiannidis, I., Athanasiadis, A., & Dagklis, T. (2023). Fetal Growth Restriction: A Comprehensive Review of Major Guidelines. *Obstetrical & Gynecological Survey*, 78(11), 690-708. doi: 10.1097/OGX.0000000000001203
- [11] Hani, S., Chalouhi, G., Lakissian, Z., & Sharara-Chami, R. (2019). Introduction of Ultrasound Simulation in Medical Education: Exploratory Study. *JMIR Med Educ*, 5(2), e13568. doi: 10.2196/13568
- [12] Hugh, O., Cowan, J., Butler, E., & Gardosi, J. (2023). Fetal size vs growth: comparative analysis of three models of growth velocity based on third trimester estimated fetal weights for identifying stillbirth risk. *Am J Obstet Gynecol*, 2023, S0002-9378(23)02188-9. Online ahead of print. doi: 10.1016/j.ajog.2023.12.029
- [13] Khmyzov, S., Yakushkin, Y., & Katsalap, Y. (2021). Нестабільність колінного суглоба за умов уроджених вад розвитку нижніх кінцівок (огляд літератури) [Knee joint instability in conditions of congenital malformations of the lower extremities (literature review)]. *Ортопедія, травматологія та протезування=Orthopaedics Traumatology and Prosthetics*, 1, 80-85. doi: 10.15674/0030-59872021180-85
- [14] Kim, M. J., Hutcheon, J. A., Lee, A. F., & Liauw, J. (2024). Autopsy-Based Growth Charts May under-Detect Fetal Growth Restriction at Autopsy. *Fetal and Pediatric Pathology*, 1-10. doi: 10.1080/15513815.2023.2299491
- [15] Kiserud, T., Piaggio, G., Carroli, G., Widmer, M., Carvalho, J., Neerup Jensen, L., ... & Platt, L. D. (2017). The World Health Organization fetal growth charts: a multinational longitudinal study of ultrasound biometric measurements and estimated fetal weight. *PLoS medicine*, 14(1), e1002220. doi: 10.1371/journal.pmed.1002220
- [16] Lee, S. H., Kim, T. H., Lee, H. H., Park, J., Chung, S. H., & Jeon, D. S. (2013). Length measurement of fetal long bone and fetal anomaly detection. *Webmed Central Obstetrics and Gynaecology*, 4(5), WMC004236. doi: 10.9754/journal.wmc.2013.004236
- [17] Levitskiy, A. F., & Benzar, I. M. (2019). *Основи діагностики, лікування та реабілітації вад розвитку опорно-рухового апарату в дітей [Basics of Diagnosis, Treatment and Rehabilitation of Developmental Defects of the Musculoskeletal System in Children]*. Тернопіль: Укрмедкнига=Тернопі: Ukrmedknyg.
- [18] Matsubara, Y., Higaki, T., Tani, C., Kamioka, S., Harada, K., Aoyama, H., ... & Awai, K. (2020). Demonstration of Human Fetal Bone Morphology with MR Imaging: A Preliminary Study. *Magnetic Resonance in Medical Sciences*, 19(4), 310-317. doi: 10.2463/mrms.mp.2019-0105
- [19] Mascherpa, M., Pegoire, C., Meroni, A., Minopoli, M., Thilaganathan, B., Frick, A., & Bhide, A. (2023). Prenatal prediction of adverse outcome using different charts and definitions of fetal growth restriction. *Ultrasound Obstet Gynecol*. Online ahead of print. doi: 10.1002/uog.27568
- [20] Merz, E., Pashaj, S., & Wellek S. (2023). Normal Fetal Growth Profile at 10-41 Weeks of Gestation - An Update Based on 10225 Normal Singleton Pregnancies and Measurement of the Fetal Parameters Using 3D Ultrasound. *Ultraschall Med*, 44(2), 179-187. doi: 10.1055/a-1968-0018
- [21] Ohuma, E. O., Villar, J., Feng, Y., Xiao, L., Salomon, L., Barros, F. C., & Papageorghiou, A. T. (2021). Fetal growth velocity standards from the Fetal Growth Longitudinal Study of the INTERGROWTH-21 st Project. *Am J Obstet Gynecol*, 224(2), 208. doi: 10.1016/j.ajog.2020.07.054
- [22] Pang, H. Q., & Gao, Q. Q. (2021). Prenatal ultrasonographic findings in Klippel-Trenaunay syndrome: A case report. *World J Clin Cases*, 9(35), 10994-10998. doi: 10.12998/wjcc.v9.i35.10994
- [23] Papageorghiou, A. T., Kemp, B., Stones, W., Ohuma, E. O., Kennedy, S. H., Purwar, M., ... & Villar, J. (2016). Ultrasound-based gestational-age estimation in late pregnancy. *Ultrasound Obstet Gynecol*, 48(6), 719-726. doi: 10.1002/uog.15894
- [24] Parikh, L. I., Nolan III, J., Tefera, E., Driggers, R. (2014). Fetal biometry: does patient ethnicity matter? *The Journal of Maternal-Fetal & Neonatal Medicine*, 27(5), 500-504. doi: 10.3109/14767058.2013.820696
- [25] Prokopchuk, N. M., Nikolenko, M. I., Korinets, Ya. M., & Ivaniv, Yu. A. (2023). Оцінка результатів пренатальної діагностики вроджених вад розвитку плоду у жінок в різні терміни гестації [Evaluation of the results of prenatal diagnostics of congenital defects of fetal development in women in different terms of gestation]. *Перспективи та інновації науки. Педагогіка. Психологія. Медицина=Prospects and Innovations of Science. Psychology. Pedagogy. Medicine*, 10(28), 796-808. doi: 10.52058/2786-4952-2023-10(28)-796-808
- [26] Romero, R. (2021). Giants in Obstetrics and Gynecology Series: Philippe Jeanty, MD, PhD, a pioneer in the study of fetal anatomy, biometry, growth, and congenital anomalies. *Am J Obstet*

- Gynecol*, 225(1), 3-9. doi: 10.1016%2Fj.ajog.2021.03.043
- [27] Tsai, A., Laor, T., Estroff, J. A., & Kasser, J. R. (2018). Constant inhibition in congenital lower extremity shortening: does it begin in utero? *Pediatric Radiology*, 48(10), 1451-1462. doi: 10.1007/s00247-018-4153-5
- [28] Yousefpour Shahrivar, R., Karami, F., & Karami, E. (2023). Enhancing Fetal Anomaly Detection in Ultrasonography Images: A Review of Machine Learning-Based Approaches. *Biomimetics* (Basel), 8(7), 519. doi: 10.3390/biomimetics8070519
- [29] Victoria, T., Shakir, N. U., Andronikou, S., Edgar, J. C., Germaine, P., Epelman, M., ... & Jaramillo, D. (2016). Normal Fetal Long Bone Length from Computed Tomography: Potential Value in the Prenatal Evaluation of Skeletal Dysplasias. *Fetal Diagnosis and Therapy*, 40(4), 291-297. doi: 10.1159/000444184
- [30] Žaliūnas, B., Jakaite, V., Kurmanavičius, J., Bartkevičienė D., Norvilaite, K., & Passerini, K. (2022) Reference values of fetal ultrasound biometry: results of a prospective cohort study in Lithuania. *Arch Gynecol Obstet*, 306(5), 1503-1517. doi: 10.1007/s00404-022-06437-z

#### ФЕТАЛЬНА УЛЬТРАЗВУКОВА АНАТОМІЯ І МОРФОМЕТРИЧНІ ПАРАМЕТРИ ВЕЛИКОГОМІЛКОВОЇ КІСТКИ

**Комар Т. В., Хмара Т. В., Процак Т. В., Заморський І. І., Ковальчук П. Є., Халатурник І. Б.**

Ультразвуковий скринінг є одним із найінформативніших методів візуалізації розвитку плода під час вагітності. Під час стандартних ультразвукових досліджень вимірюють довжину стегнової кістки плода. Проте, у випадку, якщо існує підозра на будь-яку скелетну дисплазію або затримку внутрішньоутробного розвитку, необхідно провести додаткове вимірювання інших довгих трубчастих кісток. Метою роботи було дослідити морфометричні параметри довжин правої і лівої великогомілкових кісток та встановити кореляційні зв'язки між ними та довжинами відповідної малогомілкової кістки, нижньої кінцівки та тім'яно-куприковою довжиною плода впродовж плодового періоду онтогенезу людини. Прижиттєве ультразвукове дослідження кісток гомілки 38 плодів людини проведено у медичному центрі "YUZKO MEDICAL CENTER" згідно з договором про співпрацю. Для проведення статистичних розрахунків використовувалися вбудовані можливості MS Excel. Встановлені дані щодо фетальної морфометрії довжин великогомілкових кісток вказують на відносно рівномірний ріст правої і лівої великогомілкових кісток упродовж плодового періоду онтогенезу людини: довжина правої великогомілкової кістки збільшується з  $24,77 \pm 2,25$  мм до  $65,32 \pm 2,20$  мм, а довжина лівої великогомілкової кістки збільшується з  $25,19 \pm 1,63$  мм до  $65,78 \pm 1,81$  мм. Аналіз кореляційних зв'язків між довжиною правої та лівої великогомілкових кісток, довжинами малогомілкових кісток, довжиною нижніх кінцівок і тім'яно-куприковою довжиною у плодів людини віком від 4 до 10 місяців внутрішньоутробного розвитку дозволив виявити достовірні сильні та середньої сили достовірні й недостовірні, переважно прямі, зв'язки у всіх вікових групах. Отримані морфометричні параметри великогомілкових кісток у плодів різного терміну гестації є важливими додатковими розмірами фетобіометрії, котрі можуть бути використані за необхідності детальної оцінки стану розвитку плода та при підозрі на уроджені аномалії.

**Ключові слова:** ультразвукова діагностика, великогомілкова кістка, морфометрія, плід, людина.

#### Author's contribution

*Komar T. V.* - research concept and design, receiving data, analysis an interpretation of data, design of the article.

*Khmara T. V.* - analysis and interpretation of data, critical review, final approval.

*Protsak T. V.* - analysis and interpretation of data, critical review, design of the article.

*Zamorskii I. I.* - analysis and interpretation of data, critical review, final approval.

*Kovalchuk P. Ye.* - analysis and interpretation of data, critical review, final approval.

*Halaturnyk I.B.* - receiving data, analysis an interpretation of data, final approval.