

# Death due to occasional pneumatic injury: typical characteristics

<sup>1</sup>Bachinskyi VT, <sup>1</sup>Pavliukovyh OV, <sup>2</sup>Malyshev VV, <sup>3</sup>Pavliukovyh ND

<sup>1</sup> Department of Forensic Medicine and Medical Law of Higher State Educational Establishment of Ukraine "Bukovinian State Medical University", Chernivtsi, Ukraine

<sup>2</sup> Chernivtsi regional bureau of forensic medical expertise, Chernivtsi health care department, Chernivtsi, Ukraine

<sup>3</sup> Department of Internal Medicine, Clinical Pharmacology and Occupational Diseases of Higher State Educational Establishment of Ukraine "Bukovinian State Medical University", Chernivtsi, Ukraine

## Abstract

Due to possessing of large number of pneumatic weapons by the population, there is a significant increase in the number of injuries, both in Ukraine and in the world, with shots from it, and therefore, the number of expert assessments of these cases in the practice of forensic experts is increasing.

**Key words:** pneumatic injury, forensic examination, death

## Smrť pri náhodnom poranení pneumatickou zbraňou: typické charakteristiky

### Abstrakt

Vzhľadom na to, že obyvateľstvo vlastní veľký počet pneumatických zbraní, dochádza k výraznému nárastu počtu zranení nimi spôsobenými, ako na Ukrajine, tak aj vo svete. Z tohto dôvodu sa počet expertných posúdení týchto prípadov v súdnolekárskej praxi zvyšuje.

**Kľúčové slová:** poranenie pneumatickou zbraňou, súdnolekárske vyšetrowanie, smrť

### Correspondence address:

Viktor T. Bachinskyi, MD, Prof  
Department of Forensic Medicine and Medical Law  
Higher State Educational Establishment of Ukraine  
Bukovinian State Medical University  
Kyshinivska 2  
58000 Chernivtsi  
Ukraine  
e-mail: sudmed@bsmu.edu.ua

## Introduction

There are a number of assumptions about the classification of pneumatic weapons, some authors name it as molten, another classification suggests it as firearms, the third one – as "pneumatic". Shooting of this type of weapon, which, in its pathogenesis, lead to a number of injuries and result in fatal consequences, are wide-spread all over the world nowadays.

## Aim

To describe a case report of death from accidental damage at shot with a pneumatic rifle.

## Materials and methods

Forensic medical examination of the corpse D, 2005 year of birth, was performed in the department of forensic examination of corpses of the Chernivtsi regional bureau of forensic medical expertise with means of laboratory examinations.

Although in accordance with paragraph 1.3 of the Instruction "On the procedure for the manufacturing, acquisition, storage, accounting, transportation and use of firearms, pneumatic, cold and chilled weapons, national production equipment for the shooting of cartridges equipped with rubber or similar properties of non-lethal metal flares, and cartridges

for them, as well as ammunition for weapons, major parts of weapons and explosives", the main tasks of the police are to prevent the violation of the order of manufacture, purchase, storage, accounting, protection, transportation and use of firearms, pneumatic weapons with a caliber of more than 4,5 mm and a balloon speed of over 100 meters per second and cold weapons (crossbows, bows with tensile force of more than 20 kg, hunting knives, etc.), devices of national production for shooting ammunition, equipped with rubber or similar in their properties non-lethal action metal shells, and ammunition for them, main parts of arms of weapons for weapons and cooled weapons, explosive materials, preventing cases of loss, theft, misuse and from unlawful purpose, inadvertently shot of a human being more and more often lead to fatal consequences.

### Results and discussion

During forensic medical examination of the corpse D., 2005 year of birth, it was found that he died in the presence of relatives in the place of residence.

The corpse is admitted for the examination without clothes. The corpse is of male gender, right body structure, satisfactory nutrition, body length is 157 cm. The corpse is evenly cooled by touch. Rigor mortis is well defined in all muscle groups. Livor mortis is of pale violet colour, located on the back surfaces of the body, during pressing on them in the back of the lumbar they become pale and restore their colour in 16,0 minutes. The neck is proportional to the length and structure of the body. The thorax is flat-cylindrical, elastic at compression. The anterior abdominal wall is located at the level of the lower edge of the edge arc.

Damage is detected in the form of a wound on the anterior surface of the chest on the right along the middle-clavicular line, in the projection of the 5th intercostal space, of round shape, with a slight precipitate along its upper edge, relatively equal edges and a defect of "minus-tissue" in the centre of the diameter 0,4 cm, the wound penetrates into the chest cavity.

During internal investigation it was detected that soft tissues of the hair part of the head from the inside surface are without hemorrhages throughout their length, the thickness of the skull's sides during cutting is 0,2-0,4 cm. Dura mater is whole, is not sutured with skull bones and soft mucous membranes, its sinuses contain moderate amount of liquid dark red blood, it can be easily separated from the bones of the skull bases and from the cranial cavity of the skull. Skull bones are without defect by touch. Pia mater is smooth, shiny, moist, of moderate blood flow, with moderate oedema. Brain gyrus are moderately expressed. Brain vessels are transparent, intima is smooth, shiny. Brain ventricles are shoal-shaped inside them clear liquor is found in moderate quantity. The substance of the brain is interspersed

with a clearly defined limit between the grey and the white matter, anaemic.

The thickness of subcutaneous fat at the level of sternum is up to 1,0 cm, at the level of stomach – up to 2,0 cm. Rib cartilages are dissected easily, sternum is whole. Organs of the chest and abdominal cavity are located correctly, the bowels of the intestines are inflated, the lungs occupy the thoracic cavity by its 2/3, the diaphragm is without defects, the height of the diaphragm dome on the right is on the level of 5<sup>th</sup> rib, on the left – on the level of the 6<sup>th</sup> rib. In the right pleural cavity there is a liquid dark red blood with convolutions in the amount of 1800 ml. In the left pleural cavity there is also a liquid dark red blood with convolutions in the amount of 200 ml. Pericardium sac is whole, its cavity contains about 5 ml of clear liquid. The muscle of the heart during section is of even blood flow, dense. Aorta intima is smooth, shiny, of yellow-lemon colour. Large venous vessels are without peculiarities. In the heart and large blood vessels there are remains of dark red blood.

Skeletal bones are whole by touch. Wound canal (Fig. 1) is a continuation of the skin defect passing through the subcutaneous fat, chest muscle, falls into the 5<sup>th</sup> intercostal space to the right of the middle-clavicular line, forming a rupture of elongated-oval shape, 0,7x0,5 cm in the size, which passes into the chest cavity and penetrates into the middle part of the right lung, forming on its surface an elongated-oval form of rupture, with dimensions 0,7x0,5cm, reaching the posterior surface of the middle lobe and passing to the lower part of the right lung, damaging the thoracic aorta, moving through all its thickness, directed from top to bottom, from right to left. In the thickness of the lower part of the left lung cone-shaped metal ball, 7,0 mm in length and 4,5 mm in diameter, is found. A wound from the anterior surface of the chest on the right and 4<sup>th</sup>-6<sup>th</sup> ribs from the right part of the chest are taken for forensic examination.

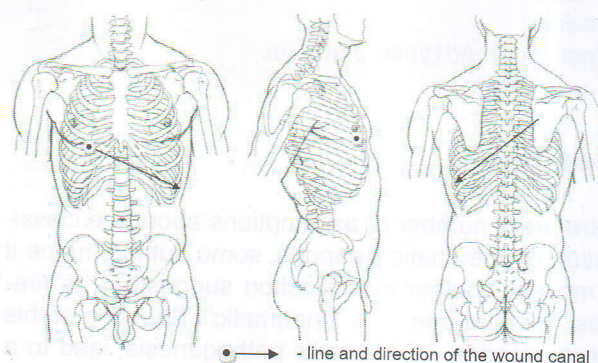


Fig. 1 Scheme of the wound canal direction

In the skin of the thorax on the right (Fig. 2,3) in its central part percutaneous damage of round shape, 0,3 mm in diameter, with relatively direct small-finifestic edges, which are compared with the defect of the tissue, forming the sign "minus tissue", was detected. Around the perimeter skin defect with the largest width of 0,2 cm, most pronounced at its right end, with moderately dense and slightly funnel-like

sealed edges was found. These features are typical for incoming fire outlet, which was formed as a result of a single shot of pneumatic weapons, equipped with a shotgun.

A set of contact patterns has been carried out using the method of obtaining colour prints with the successive use of alkaline and acid solvent reagents, and with corresponding adding of rubyano-hydrogen acid and sodium sulfide. On the received contactograms we didn't find any coloration, which could indicate the presence of traces of copper, nickel, cobalt or lead. Hemorrhage in the soft tissues of the 5th intercostal space, of oval shape, 1,2x0,9 cm in size, was detected. There were no any damages or violations of the anatomical integrity of the investigated fragments of right 4<sup>th</sup>, 5<sup>th</sup>, 6<sup>th</sup> ribs.




Fig. 2 Skin (outer side)




Fig. 3 Skin (inner side)

The diagnosis was established: Bullet penetrating blind wound of the chest with damage of right and left lungs, aorta. Complication: Massive internal hemorrhage.

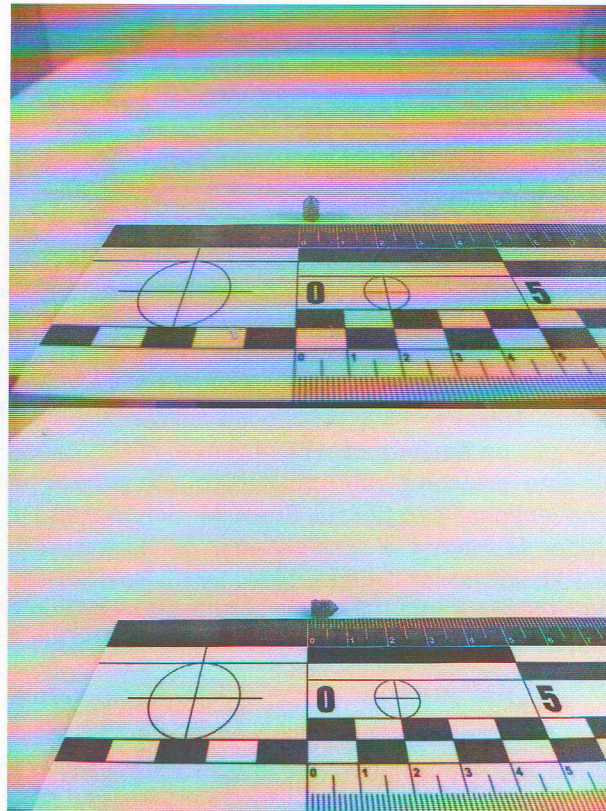


Fig. 4, 5 Metal shell found in the thickness of the left lung

Injuries described in this paper appeared in succession one after another, shortly before the moment of death as a result of impact of a hard blunt object, the features of which is possessed by a pneumatic gun (including a caliber of 4,5 mm), as evidenced by: a defect of "minus-tissue", direction of the wound canal from top to bottom, from right to left, cone-shaped metal ball found in the thickness of the left lung (Figure 4, 5), 0,7 cm in length, 4,5 mm in diameter, the data of medical-forensic examination, shown peculiarities of the incoming fire-hole, which is formed as a result of a single shot of pneumatic weapons, equipped with a shotgun.

### Conclusions

Therefore, the use of 4,5 mm calibers can lead to deadly injury in conditions of circumstances and external factors, such as absence of many layers of clothing, and their breakthrough force is sufficient for immersion into the body and injuries of internal organs with lethal consequences.

References

1. Evaluation of brain damage resulting from penetrating and non-penetrating stunning in Nelore Cattle using pneumatically powered captive bolt guns Oliveira SEO, Dalla Costa FA, Gibson TJ, Costa OAD, Coldebella A, Gregory NG Meat Sci. 2018 Nov;145:347-351. doi: 10.1016/j.meatsci.2018.07.016.
2. Serious injury and fatality investigations involving pneumatic nail guns, 1985-2012. Lowe BD, Albers JT, Hudock SD, Krieg EF. Am J Ind Med. 2016 Feb;59(2):164-74. doi: 10.1002/ajim.22560.
3. The classification of the injuries inflicted to the human body by gunshots from the pneumatic weapons. Kozachenko IN. Sud Med Ekspert. 2016 Jul-Aug;59(4):10-14. doi: 10.17116/sud-med201659410-14
4. Ballistic parameters of .177 (4.5 mm) caliber plastic-sleeved composite projectiles compared to conventional lead pellets. Frank M, Schönekeß H, Jäger F, Herbst J, Ekkernkamp A, Nguyen TT, Bockholdt B. Int J Legal Med. 2013 Nov;127(6):1125-30. doi: 10.1007/s00414-013-0904-x. Epub 2013 Aug 29.
5. Penetrating Cardiac Nail Gun Injury in a Child. Kulaylat AN, Chesnut CH 3rd, Patel S, Rocourt DV, Clark JB. Pediatr Emerg Care. 2016 Aug; 32(8):536-7. doi: 10.1097/P E C . 0000000000000449
6. The possibilities for the medical assessment of the injuries inflicted by the darts fired from the pneumatic rifles. Makarov IJ, Bajbarza NV, Lorents AS. Sud Med Ekspert. 2015 Jul-Aug;58(4):15-18. doi: 10.17116/sudmed201558415-18.
7. Air gun injury with deadly aftermath--case report. Stankov A, Jakovski Z, Pavlovski G, Muric N, Dwork AJ, Cakar Z. Leg Med (Tokyo). 2013 Jan; 15(1):35-7. doi: 10.1016/j.legalmed.2012.08.004. Epub 2012 Sep 25.
8. Delayed presentation of traumatic cerebral and dural arteriovenous fistulae after a BB gun accident in a pediatric patient: case report. Abila AA, Albuquerque FC, Theodore N, Spetzler RF. Neurosurgery. 2011 Jun;68(6):E1750-4; discussion E1754-5. doi: 10.1227/NEU.0b013e31821713fb.