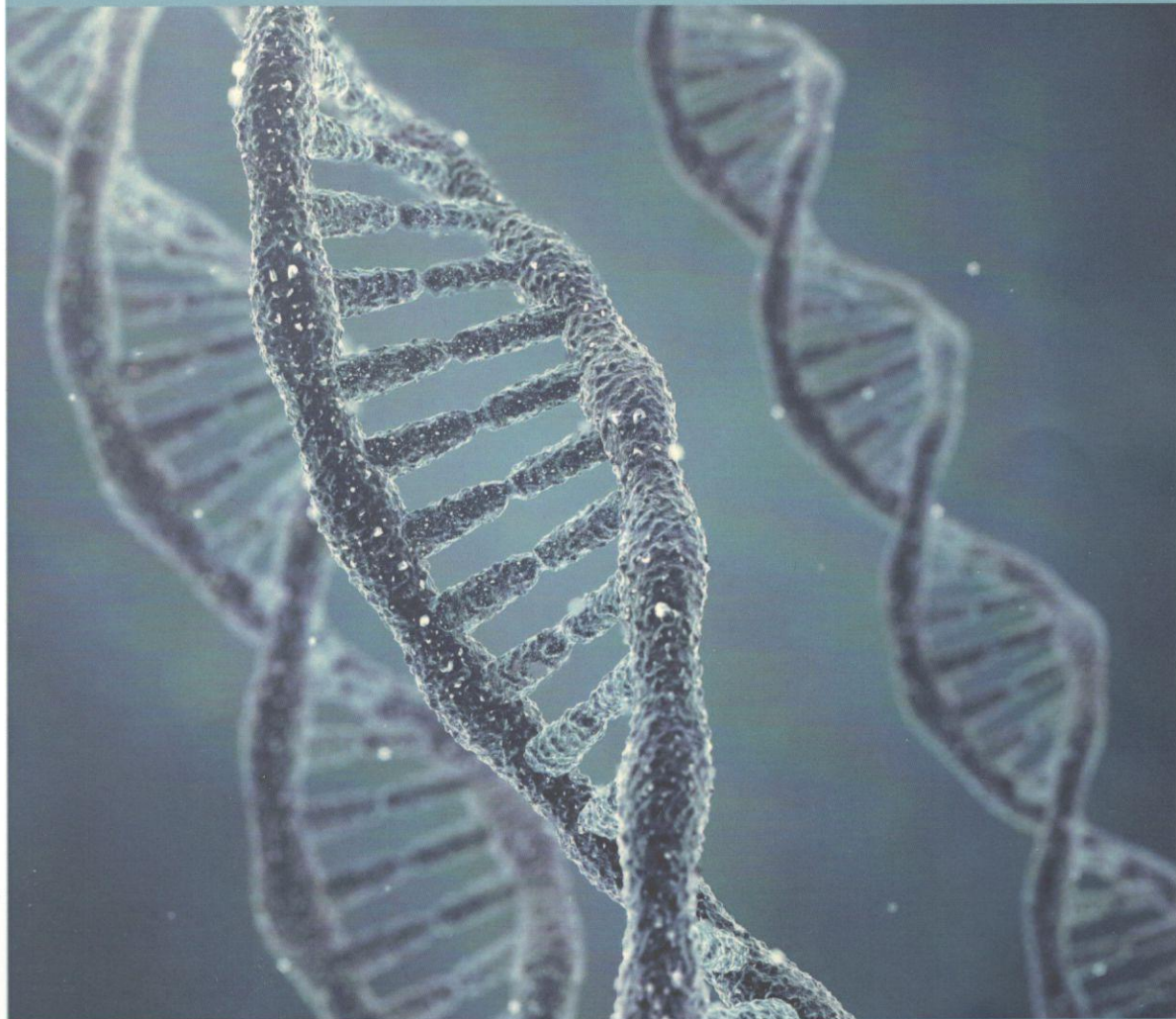


**2**  
**2015**

**European Journal  
of Biomedical  
and Life Sciences**



**ISSN 2310-5674**

**Austria, Vienna**



# Contents

<b>Section 1. Clinical medicine .....</b>	<b>3</b>
<i>Abdikarimov Fakhridin Bakhramovich, Navruzov Kuralbay Navruzovich,</i>	
<i>Khujatov Nurbek Jumabaevich, Babajanova Yulduz Ikrombayevna</i>	
Ultrasonic methods determining volume of cavities of ventricles of the heart .....	3
<i>Bychkov Eugene Nikolaevich, Borodulin Vladimir Borisovich,</i>	
<i>Barylnik Julia Borisovna, Samoylova Daria Dmitrievna,</i>	
<i>Filippova Natalia Valerevna</i>	
The analysis of detoxication genes' polymorphism at development of a "detoxication syndrome" in drug-addicted patients with various experience of narcotics use .....	8
<i>Dmitrieva Oksana Alekseevna, Leonenko Ekaterina Andreevna,</i>	
<i>Vozhzhova Victoria Nicolaevna, Pisanko Gennady Gennadevich,</i>	
<i>Karpov Sergey Mihailovich, Shevchenko Peter Petrovich</i>	
The degree of disorder of the patients' psycho-emotional sphere with epilepsy .....	14
<i>Vakoliuk Olena Borysivna, Budaev Iurij Viktorovich,</i>	
<i>Kosteniuk Snizhana Virzelivna</i>	
The main aspects of the clinic picture, treatment and prevention of caries and periodontal tissues of children patients with epidermolysis bullosa .....	16
<i>Hodovanets Oksana, Vitkovskiy Oleksandr</i>	
Zinc: clinical-biochemical aspects of dental and thyroid pathology in children .....	19
<i>Jamantayeva Maria Shokbarovna, Yerkinbekova Bakyt Kadirchanovna,</i>	
<i>Naribay Roza Jumbaikyzy</i>	
Comparative analysis of organic mental disorders combined or non-combined with somatic pathology .....	22
<i>Zakirova Lola</i>	
Breast cancer screening programme implementation for fertile age women in the Republic of Uzbekistan .....	24
<i>Kolenko Yulia Gennadievna</i>	
Estimation of the state of the tissues of periodontium in patients with the cardiovascular diseases .....	28
<i>Norbert Torma, Kopolovets Ivan, Sihotsky Vladimir,</i>	
<i>Kubikova Maria, Frankovičova Maria</i>	
Paragangliomas in the area of carotid bifurcation – case reports .....	32
<i>Kuziyev Otabek Jurakulovich, Ortiqboyev Jakhongir Ortiqboy ogli,</i>	
<i>Khakimova Gulnoz Golibovna, Aripdjanova Nigina Bahromdjanovna</i>	
Peculiarities of dermatoglyphic values among the people of Uzbek population dependently on sex .....	35
<i>Mamedova Guzalya Bakirovna, Akbarhodjaev Aziz Ahrarovich,</i>	
<i>Isaev Ilshod Sultanovich, Odilova Madina Abduljalilovna</i>	
Development the marketing department in medical institutions .....	38
<i>Sannikov Pavel Germanovich, Kuznecov Pavel Borisovich,</i>	
<i>Styazhkina Svetalana Nikolaevna, Kuklin Dmitry Nikolaevish,</i>	
<i>Gabsalikov Ruslan Salimyanovich, Ivashchenko Viktor Vladimirovish,</i>	
<i>Sirazov Zufar Saybanovich, Subotnikov Maksim Vacheslavovich</i>	
Benign prostatic hyperplasia. Description of a clinical case .....	41

wipes for oral hygiene. A child with epidermolysis bullosa should be examined orally not less than twice a year because caries grows very fast. After all the baby teeth have appeared it is important to conduct preventive coating varnish with fluor, nearly ten procedures. It is important to brush the teeth at least once a day and to water the mouth after each meal. The parents of sick children should brush their childrens' teeth till they are seven.

5. Presently, children with epidermolysis bullosa can fully preserve their teeth both functionally and cosmetically. Modern dentistry can prevent tooth decay, restore the affected enamel and help form a correct bite. The future is much more optimistic: new materials are being worked out, more aesthetic and firmer, new technologies continue to be carried out. And healthy teeth of the patient with epidermolysis bullosa will become the reality.

### References:

1. Zverkova F. A. Skin diseases of the infants. // SOTIS, 1994. – 235 p.
2. Caine Kay Shu-May, Lio Peter A., Stratigos Alexander J., Johnson Richard Allen. Children dermatology. Atlas and directory. (translation from English by Ivanova O. L., Lvova A. N.) // Publishing house Binom. Laboratory of knowledge. – 2011. – 496 p.
3. Ryzhko P. P. Genedermatoses: epidermolysis bullosa. / Ryzhko P. P., Fedota A. M., Voronzov V. M. – Kharkov: OBERIG, 2009. – 187p.
4. Ryzhko P. P. Genedermatoses: epidermolysis bullosa, ichthyosis, psoriasis: the manuscript. / Ryzhko P. P., Fedota A. M., Voronzov V. M. – Kharkov: Folio, 2004. – 334 p.
5. Ryzhko P. P., Fedota A. M., Voronzov V. M. Epidermolysis bullosa in Ukraine: Ukrainian children need help. // newspaper News of pharmacy and medicine. – 17 (430), – 2012. – P. 18–19.
6. Yan E. G., Paris J. J., Ahluwalia J., Lane A. T., Bruckner A. L. Treatment Decision-making for Patients with the Herlitz Subtype of Junctional Epidermolysis Bullosa. // J Perinatol. – 2007, May – 27 (5) – P. 307–11.

*Hodovanets Oksana,  
Bukovinian State Medical University,  
Associate Professor, the Faculty of Dentistry  
E-mail: oksana-godovanets@yandex.ru*

*Vitkovskiyi Oleksandr,  
Bukovinian State Medical University,  
Assistant, the Faculty of Dentistry  
E-mail: atolsik@gmail.com*

## Zinc: clinical-biochemical aspects of dental and thyroid pathology in children

**Abstract:** the content of zinc is detected in the hard tissues of the tooth in case of caries process in children with comorbid pathology of the thyroid gland. Application of a complex vitamin-mineral zinc containing preparation was found to be reasonable in this group of children.

**Keywords:** children, zinc, caries, exophthalmic non-toxic goiter.

Nowadays the position concerning the role of general factors in the development of caries process in children has been clearly defined. In addition to somatic pathology and caries provoking diets, natural and ecological factors are always present. The influence of biogeochemical environment is of

great importance on occurring pathology of the hard dental tissues as well as a number of other diseases of the human body, and thyroid gland in particular. In other words, dental caries and exophthalmic non-toxic goiter are diseases closely connected with trace elements impact. The role of halogens in occurring



these diseases is well known, although much less works deal with the influence of essential micronutrients including zinc.

Children are more susceptible to zinc deficiency than adults, as this trace element affects their rate of growth. Every cell division requires involvement of zinc-dependent enzymes: RNA-polymerase and reverse transcriptase. Zinc plays an essential role in the synthesis of polyribosomes and collagen, thus in the formation of the osseous tissue [1, 389–394].

Zinc is contained in the nuclear receptor  $T_3$ , (so-called “zinc fingers”), and by means of binding with DNA it regulates gene expression and synthesis of specific proteins in the cell, which becomes evident due to physiological effects of thyroid hormones [5, 539–543; 7, 3860–3866].

According to the findings of the investigation conducted by M. Ozata et al. combined zinc and iodine deficiency in Turkey plays a certain role in the development of exophthalmic goiter [4, 211–216], although, in some other investigations conducted in Iran [8, 58–61; 3, 287–290] and Germany [6, 12–15], the relation between zinc deficiency and development of exophthalmic goiter was not found.

Table 1. – The findings of the investigation of the trace element content in the dental hard tissues

Group	Zinc content	
	mcg/g of ashes	mcg/g of dry substance
I group (n=7)	128.83 ± 9.51	9.73 ± 0.59
II group (n=9)	170.85 ± 10.34*	14.89 ± 0.98*
IIIA group (n=5)	137.31 ± 9.85	5.19 ± 0.24*
IIIB group (n=4)	113.06 ± 7.52*	6.31 ± 0.35*

Note: \* – reliable probability of the indices in I and II, III groups,  $p < 0,05$

It should be noted that the level of trace elements in biological substrates not always reflects their body requirements. Frequently in case of micronutrient deficiency its high level is found in such biological substrates as hair, nails etc. the mechanism of such accumulation consists in the formation of trace element complexes with proteins — metaloproteins, and their accumulation in the tissues with low metabolic rate. These complexes do not affect the tissues, but make the metabolic rate of a certain trace element lower, and thus, they make it not easily accessible for quick involvement in trace element dependent functions of the

In this connection, the objective of our work was to detect zinc content in the hard dental tissues in case of caries process in children with comorbid pathology of the thyroid gland, and conduct its correction.

Clinical dental examination of 65 children of 12 years of age was performed. The groups of observation were formed in the following way: 20 somatically healthy children (I group); 20 somatically healthy children with caries (II group); 25 children with exophthalmic non-toxic goiter (ENTG) and caries affliction (III group). In its turn, III group was divided into two subgroups: IIIA — children with ENTG of Ia degree, and IIIB — children with ENTG Ib-II degrees. In the teeth extracted during physiological changes zinc content was determined by means of anatomical-absorptive spectrophotometric method.

The spread of caries process in children of all the groups was more than 80 %, that is, it was rather high according to evaluation criteria suggested by the WHO. The indices of caries spread was markedly increased in the groups with increased severity of thyroid pathology.

The findings of the investigation of the trace element content in the dental hard tissues are presented in Table 1.

organism. Clinically in such cases microelementosis may occur [1, 123–167; 2, 54–68].

The human body does not synthesize micronutrients, it has either mechanisms of their depot for a long time, that's why they should be constantly taken with food in an adequate amount and be well-balanced according to physiological, age, and later with gender peculiarities of children and teen-agers. Usually trace elements should be supplemented.

In our research we have added zinc like a complex vitamin-mineral preparation containing magnesium, copper, manganese and zinc. The latter in the amount of 7.5 mg. was contained in zinc oxide.



Children took the drug per one tablet once a day at a meal time during one month twice a year. Administration of the drug was conducted against the ground of basic iodotherapy considering a child age. This complex of treatment was performed for 12 children

from III group. The control group for comparison included 12 children from the same group who underwent oral sanitation only.

The findings of clinical dental observation of III group of children are presented in Table 2.

Table 2. – The findings of clinical dental observation of III group of children

	Intensity of caries		Number of caries complications	
	Group of observation (n=12)	Control group (n=12)	Group of observation (n=12)	Control group (n=12)
Before treatment	4.2 ± 0.37	4.0 ± 0.28	50.0 %	50.0 %
After treatment	4.1 ± 0.35	4.0 ± 0.28	41.7 %	50.0 %
Half a year after treatment	4.2 ± 0.37	4.3 ± 0.26	41.7 %	58.3 %
A year after treatment	4.2 ± 0.37	4.7 ± 0.31	41.7 %	58.3 % **
Two years after treatment	4.2 ± 0.37	5.2 ± 0.49 * **	41.7 %	66.7 % * **

Note: \* – a reliable difference of indices before and after treatment,  $p < 0.05$ ; \*\* – a reliable difference of indices of the group of observation and control,  $p < 0.05$

Intensity of caries in children with exophthalmic non-toxic goiter at the beginning of treatment was within 4.0–4.2, and had correlation dependence due to severity of somatic disease. During two years the indices of caries intensity in the group of observation did not increase, and on the contrary, in the group of comparison a clear dynamics to the increase of the indices of caries intensity was found.

Different forms of pulpitis and periodontitis of the permanent teeth were registered in half of the examined children before treatment. Chronic forms of pulpitis and periodontitis prevailed in all the

children. Chronic fibrous pulpitis was found most frequently. After the suggested medical correction a number of new complications reduced, which is indicative of increased resistance of the hard dental tissues to caries in children.

Therefore, administration of the preparations containing macronutrient elements and trace elements against the ground of basic iodotherapy in children with exophthalmic non-toxic goiter enables to stabilize intensity of dental caries, increase the level of dental health and prevent the development of possible complications of the oral system and child body on the whole.

### References:

1. Oberlis D. Biologicheskaja rol' makro- i mikrojelementov u cheloveka i zhivotnyh./D. Oberlis, B. Harland, A. Skal'nyj. – SPb.: Nauka, 2008. – 544 p.
2. Skal'nyj A. V. Biojelementy v medicine./A. V. Skal'nyj, I. A. Rudakov. – M.: ONIKS 21 vek, 2004. – 272 p.
3. High prevalence of goiter in schoolchildren in Isfahan; zinc deficiency does not play a role./A. H. Keshteli, M. Hashemipour, M. Siavash et al.//Endokr. Pol. – 2010. – Vol. 61 (3). – P. 287–290.
4. Iodine and zinc, but not selenium and copper, deficiency exists in a male Turkish population with endemic goiter./M. Ozata, M. Salk, A. Aydin et al.//Biol. Trace Elem. Res. – 1999. – Vol. 69 (3). – P. 211–216.
5. Oppenheimer J. H. Evolving concepts of thyroid hormone action./J. H. Oppenheimer//Biochimie. – 1999. – Vol.5. – P. 539–543.
6. Serum zinc levels and goitre epidemiology in Germany./R. Hampel, T. Kuhlberg, K. P. Schneider et al.//Zeitschr. Ernährungswiss. – 1997. – Vol. 36 (1). – P. 12–15.
7. Tata J. R. The road to nuclear receptors of thyroid hormone./J. R. Tata//Biochim. Biophys. Acta. – 2013. – Vol. 7. – P. 3860–3866.
8. Zinc status and relation to thyroid hormone profile in Iranian schoolchildren./M. H. Dabbaghmanesh, A. Sadegholvaad, F. Zarei, G. Omrani//J. Tropical Pediatrics. – 2008. – Vol. 54 (1). – P. 58–61.