

## ANATOMY OF THE INTERNAL FEMALE GENITAL ORGANS IN 7-MONTH-OLD HUMAN FETUSES

*D.V.Proniaiev, F.D.Marchuk, T.V.Khmara*

*Bukovinian State Medical University (Chernivtsi)*

---

### АНАТОМІЯ ВНУТРІШНІХ ЖІНОЧИХ СТАТЕВИХ ОРГАНІВ У 7-МІСЯЧНИХ ПЛОДІВ ЛЮДИНИ

**Резюме.** При дослідженні 7-місячних плодів жіночої статі виявлено варіанти топографії внутрішніх органів та кровоносних судин таза. В статті описані особливості форми та синтопії яєчників, маткових труб, наведені морфометричні особливості загальної, зовнішньої та внутрішньої клубових артерій.

**Ключові слова:** яєчник, матка, маткова труба, плід.

---

The practical significance of anatomical studies in the perinatal period of ontogenesis is stipulated by the introduction into medical practice of modern methods of prenatal diagnostics (an ultrasound examination of the fetal development, CT, MRT), prenatal surgical correction of abnormalities [1, 2].

Odd bibliographical data, dealing with the specific characteristics of the morphogenesis and forming of the topography of the uterus, ovaries, uterine tubes in human fetuses of different age groups are ascertained [3-5]. The information pertaining to individual anatomical variability of the organs and structures of the female genital system and formation of their correlative interrelations in the perinatal period of the development is largely fragmentary and is based on the material obtained from diverse age groups the latter requiring further research.

**The object of the research:** to ascertain the specific characteristics of the formation of the syntopy of the internal female genital organs in 7-month old human fetuses.

**Material and methods.** The study was carried out on 11 human fetuses aged 7 months – measuring 231.0-270.0 mm of the parietococcygeal length (PCL). The material was fixed in a 7% formol solution during a fortnight upon which the specific characteristics of the external structure of the internal female genital organs and their syntopy were studied, employing the method of thin sectioning under the control of a binocular magnifier and morphometry.

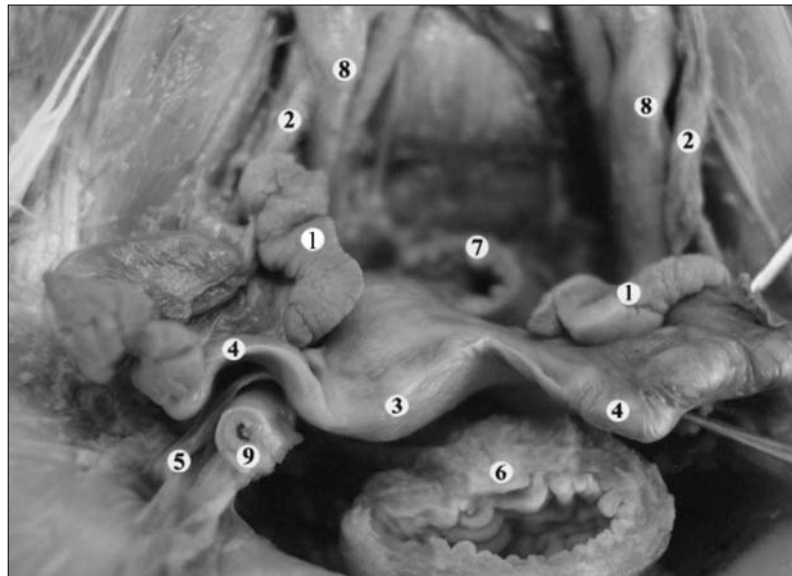
**The results of the investigations and their discussion.** The ovaries of fetuses aged 7-month are largely of an elongated, flattened, irregular oval form located in the cavity of the large pelvis. The right ovary, as a rule, is located above the left one. The right ovaries predominantly occupied a vertical position, while the left ones – an oblique position. The length of the ovarian mesenteries is considerably less than the length of the ovaries themselves. Fluctuations of the width of the ovaries are insignificant. The most significant is the length of the ovaries. We have revealed a predominance of the length of the right ovary over the length of the left one within the range of 1.0 mm up to 1.8 mm. The morphometric parameters of some internal genital organs are presented in the table.

The length of the tubal margin of the mesentery exceeds the length of the ovarian margin by  $3.0 \pm 0.4$  mm. The mesentery of the tube is restricted: laterally – by the suspensory ligament of the ovary, medially – by the ligamentum ovarii proprium. The uterine tube in 8 fetuses is located horizontally in the cavity of the large pelvis, in 4 fetuses – obliquely. The fimbriae of the tube have the appearance of short lamellar processes. The lateral portion of the ampulla is wider ( $5.0 \pm 0.7$  mm) than the medial one ( $2.5 \pm 0.3$  mm). There is the greater psoas muscle, the genitofemoral nerve, external iliac vessels behind the ampulla. The right umbilical artery and the proper ligament of the ovary adjoin the isthmus of the uterine tube behind. The

Table

**Morphometric indices of the internal female genital organs  
in 7-month-old human fetuses**

Parameters	Measurement (mm)
The length of the right uterine tube	22,5±2.0
The length of the mesentry of the right uterine tube	13.5±3.0
The length of the left uterine tube	19.0±3.0
The length of the mesentry of the left uterine tube	11.5±2.0
The length of the right ovary	14.5±3.0
The length of the left ovary	12.5±2.0



*Fig. The internal femal genital organs of a fetus, measuring 265 mm of the of parietococcygeal length. Micropreparations. A 1,5<sup>x</sup> magnification: 1 – the ovary; 2 – the external iliac artery; 3 – the uterus; 4 – the uterine tube; 5 – the round ligament of the uterus; 6 – the urinary bladder; 7 – the rectum; 8 – the ureter; 9 – the right umbilical artery.*

right ovary is to be found over the tube, the loops of the ileum being in front of it. The ovary in the 8 fetuses is flattened, having an elongated oval form, in 3 cases it is of an irregular trihedral form. Due to a high localization of the fundus and the body of the uterus in the abdominal cavity both mesenteries of the uterine tube take part in the formation of the broad ligament of the uterus. The left uterine tube is located obliquely in all the fetuses under study. The fimbriae of the uterine tube are in the form of short laminar processes. The funnel and fimbriae in 7 fetuses adjoin the genitofemoral nerve, in 4 fetuses – the femoral nerve. Behind the ampulla of the tube the external iliac vessels, the ureter, the left umbilical artery are found. The ligamentum ovarii proprium adjoins tightly the isth-

mus behind, in front – the round ligament of the uterus. The ovary adjoins the medial surface of the tube, in front of the tube there is the sigmoid colon. In 7 fetuses the left ovary is flattened, having an elongated oval form, in 4 – it is of an irregular trihedral form (Figure).

In one case ( the fetus measuring 245 mm of the PCL) the length of the right ovary, as well as the length of the right uterine tube exceeded considerably the length of the left ovary and the left uterine tube and equalled respectively: the length of the right ovary – 22.5 mm, whereas the length of the left ovary – 12.8 mm; the length of the right uterine tube – 28.6 mm and the length of the left uterine tube – 19.2 mm. There is every reason to regard such a marked advantage of the morphome-

tric parameters of the right ovary, the right uterine tube over the corresponding parameters of the left ovary and the left uterine tube to be pathologic asymmetry.

**Conclusions and prospects of further studies.** 1. Asymmetry of the position and measurements of the ovaries is observed in 7-month – old

fetuses; the length of the right ovary prevails over the left one. We consider a somewhat greater length of the right ovary than the left one to be physiological asymmetry. 2. The research carried by us is indicative of a need of studying the variant anatomy of the internal female genital organs during the perinatal period of the development.

### Bibliography

1. Ахтемійчук Ю.Т. Гистотопографія яєчників людини в плодному періоді розвитку / Ю.Т.Ахтемійчук, В.Ф.Марчук // *Акт. пробл. морфології: сб. тр. Міжнарод. науч.-прак. конф., посв. 85-літтю Білоруського гос. мед. ун-та.* – Мінськ, 2006. – С. 10.
2. Ахтемійчук Ю.Т. Особливості будови та синтопії внутрішніх жіночих статевих органів у 10-місячних плодів людини / Ю.Т.Ахтемійчук, В.Ф.Марчук // *Наук. потенціал світу – 2005: матер. II Міжнар. наук.-прак. конф. (Дніпропетровськ, 19-30 вересня 2005 р.).* – Т. 20, "Медицина". – Дніпропетровськ: Наука і освіта, 2005. – С. 35-36.
3. Манчуленко Д.Г. Топографоанатомічна характеристика прямокишково-маткової заглибини у плодів людини / Д.Г.Манчуленко, В.М.Круцяк, Ю.Т.Ахтемійчук, Т.В.Хмара // *Укр. мед. альманах.* – 2000. – Т. 3, № 3. – С. 111-113.
4. Марчук В.Ф. Синтопія яєчників у плода людини 4-місяців / В.Ф.Марчук, О.В.Дибель, Ю.Ф.Марчук // *Від фонд. досліджень – до прогр. в медицині: матер. наук.-прак. конф. з міжнар. участю, присв. 200-річчю з дня заснування Харківського держ. мед. ун-ту (Харків, 17-18 січня 2005 р.).* – Харків, 2005. – С. 6.
5. П'ятницька Т.А. Гистотопографія маткових труб у 10-місячних плодів / Т.А.П'ятницька // *Анатомо-хірургічні аспекти дитячої гастроентерології: матер. 2-го Наукового симпозиуму (Чернівці, 21 травня 2010 р.) / за ред. проф. Ю.Т.Ахтемійчука.* – Чернівці, 2010. – С. 98-99.

### АНАТОМИЯ ВНУТРЕННИХ ЖЕНСКИХ ПОЛОВЫХ ОРГАНОВ У 7-МЕСЯЧНЫХ ПЛОДОВ ЧЕЛОВЕКА

**Резюме.** При исследовании 7-месячных плодов женского пола установлены варианты топографии внутренних органов и кровеносных сосудов таза. В статье описаны особенности формы и синтопии яичников, маточных труб, приведены морфометрические особенности общей, внешней и внутренней подвздошных артерий.

**Ключевые слова:** яичник, матка, маточная труба, плод.

### ANATOMY OF THE INTERNAL FEMALE GENITAL ORGANS IN 7-MONTH-OLD HUMAN FETUSES

**Abstract.** While studying female 7-month old fetuses, variants of the topography of the internal organs and the blood vessels of the pelvis were detected. The paper describes the specific characteristics of the form and syntopy of the ovaries, uterine tubes, the morphometric peculiar features of the common, external and internal iliac arteries are presented.

**Key words:** ovary, uterus, uterine tube, fetus.

Bukovinian State Medical University (Chernivtsi)

Надійшла 09.03.2011 р.

Рецензент – проф. О.А.Андрієць (Чернівці)