

2. Александрова О.С. Факторный анализ проявлений полиорганной недостаточности и их роли в наступлении неблагоприятного исхода у пострадавших с сочетанной травмой живота / О.С. Александрова, Ю. М. Гаин. // Мед. журн.. – 2009. – №2. – С. 19–23.
3. Лисенко Б.П. Прогнозування перебігу травматичної хвороби при політравмі / Б.П.Лисенко, В.Д. Шейко // Клін. хірургія. – 2000. – №5. – 16 с.
4. Пугачёв А. Н. К оценке результатов лечения пострадавших с множественной и сочетанной травмой органов брюшной полости / А. Н. Пугачёв. // Вестник РУДН. – 2010. – №2. – С. 117–118.
5. Селезнёв С. А. Травматическая болезнь и её осложнения. / С.А. Селезнёв, С.Ф. Багненко, Ю.Б. Шапот. // СПб: Политехника. – 2004. – №1. – С. 12–27.
6. Marshall J.C. Multiple organ dysfunction score: a reliable descriptor of a complex clinical outcome / J.C. Marshall // Crit. Care Med. – 1995. – Vol. 23. – P. 1638–1652.
7. Meldrum D.R. Prospective characterization and selective management of the abdominal compartment syndrome / D.R. Meldrum // The Am. J. of Surgery. – 1997. – Vol. 174, N 6. – P. 667–673.
8. Rosemary K.L. Intra-abdominal Hypertension and Abdominal Compartment Syndrome / K.L. Rosemary // Critical Care Nurse. – 2012. – Vol 32, N 1. – P. 19–31.

## REFERENCES:

1. Abdominal'ni poshkodzhennya pri dorozhn'o–transportnij travmi / [M.G. Kononenko M. G., S. P. Korobova S. P., L. G. Kashchenko L. G. ta in.]. // Visn. Vinnic'kogo nac. med. un-tu. – 2010. – №14. – S. 351–353.
2. AAleksandrova O.S. Faktornyj analiz proyavlenij poliorgannoї nedostatochnosti i ih roli v nastuplenii neblagopriyatnoho iskhoda u postradavshih s sochetannoї travmoї zhivota / O.S. Aleksandrova, YU. M. Gaїn. // Med. zhurn.. – 2009. – №2. – S. 19–23.
3. Lisenko B.P. Prognozuvannya perebigu travmatichnoї hvorobi pri politravmi / B.P.Lisenko, V.D. SHejko // Klin. hirurgiya. – 2000. – №5. – 16 s.
4. Pugachyov A. N. K ocenke rezul'tatov lecheniya postradavshih s mnozhestvennoї i sochetannoї travmoї organov bryushnoj polosti / A. N. Pugachyov. // Vestnik RUDN. – 2010. – №2. – S. 117–118.
5. Seleznyov S. A. Travmaticheskaya bolezni' i eyo oslozhneniya. / S.A. Seleznyov, S.F. Bagnenko, YU.B. SHapot. // SPb: Politekhnika. – 2004. – №1. – S. 12–27.
6. Marshall J.C. Multiple organ dysfunction score: a reliable descriptor of a complex clinical outcome / J.C. Marshall // Crit. Care Med. – 1995. – Vol. 23. – P. 1638–1652.
7. Meldrum D.R. Prospective characterization and selective management of the abdominal compartment syndrome / D.R. Meldrum // The Am. J. of Surgery. – 1997. – Vol. 174, N 6. – P. 667–673.
8. Rosemary K.L. Intra-abdominal Hypertension and Abdominal Compartment Syndrome / K.L. Rosemary // Critical Care Nurse. – 2012. – Vol 32, N 1. – P. 19–31.

UDC 617.51/58-001-008.6-06:616-036.88

## TREATMENT OF NECROTIC SUPPURATIVE LESIONS IN PATIENTS WITH DIABETES MELLITUS USING REGIONAL PROLONGED OZONE THERAPY

## ЛЕЧЕНИЕ ГНОЙНО-НЕКРОТИЧЕСКИХ ПОРАЖЕНИЙ СТОПЫ У БОЛЬНЫХ С САХАРНЫМ ДИАБЕТОМ С ИСПОЛЬЗОВАНИЕМ РЕГИОНАЛЬНОЙ ПРОЛАНГИРОВАННОЙ ОЗОНОТЕРАПИИ.

### Fundyur V.D.

PhD in surgery, doctor of filosofi in medical science, Department of surgery #2, Higher educational establishment Ukraine state «Bukovinian State Med. University», Ukraine. E-mail: FoundiurW57@mail.ru Independence Avenue Str. 46, Kitsman, Chernivtsi region, Ukraine, 59300

### Grodetskyi V.K.

PhD in surgery, Assoc. Professor, Department of surgery #2, Higher educational establishment Ukraine state «Bukovinian State Medical University», Ukraine. E-mail: valentin.g75@mail.ru Boulevard of Heroes Krut St., 5/32, Chernivtsi, Ukraine, 58000

### Фундюр В.Д.

Кандидат медицинских наук, доктор философии в мед. науках, ассистент кафедры хирургии №2 ВГУЗ Украины «Буковинский гос.мед.университет», Украина, ул. Независимости, д.46, Кицмань, Черновицкая обл., Украина, 59300 E-mail: FoundiurW57@mail.ru

### Гродецкий В.К.

Кандидат мед. наук, доцент кафедры хирургии №2 ВГУЗ Украины «Буковинский гос. мед. университет», Украина ул. Бульвар Героев Крут д.5 кв.32, Черновцы, Украина, 58000 E-mail: valentin.g75@mail.ru

**Yakobchuk S.A.**

PhD in surgery, Assoc. Professor,  
Department of surgery #2, Higher educational establish-  
ment Ukraine state «Bukovinian State Medical Universi-  
ty», Ukraine. Independence Avenue 115/48, Chernivtsi,  
Ukraine, 58029

**Khomko O.Y.**

MD, PhD, Assoc. Professor,  
Department of Nursing and Higher Nursing Education  
Higher state educational establishment of Ukraine state  
«Bukovinian State Medical University», Ukraine.  
E-mail: Homko.oleg@bsmu.edu.ua  
F.Dostoevsky st., 25/3 Chernivtsi, Ukraine, 58029.

**Якобчук С.А.**

Кандидат медицинских наук, доцент кафедры  
хирургии №2 ВГУЗ Украины «Буковинский гос. мед.  
университет», Украина Просп. Независимости, д.  
115, кв. 48, Черновцы, Украина, 58029

**Хомко О.И.**

Кандидат медицинских наук, доцент кафедры  
уходу за больными и высшего медсестринского  
образования ВГУЗ Украины «Буковинский гос. мед.  
университет», Украина E-mail: Homko.oleg@bsmu.  
edu.ua ул. Ф. Достоевского, д.25 кв.3, Черновцы,  
Украина, 58029.



**Abstract:** In patients with ischemic-gangrenous form of diabetic foot syndrome intra-arterial injection of ozone-containing physiological saline made according to Seldinger method promotes decrease of glycemia level and potentiates a positive therapeutic effect of a comprehensive treatment of this category of patients. Stimulation of the macrophage functional activity under ozone effect as well as availability of destructive changes in the cells without necrotizing lesions can be explained by involvement of apoptosis mechanism as a positive factor in the regulation of local homeostasis on the final inflammatory (exudative) phase of a wound process.



**Key words:** diabetes mellitus, ozone therapy, diabetic foot syndrome, apoptosis.



**Резюме.** У пациентов с ишемически-гангренозной формой синдрома стопы диабетика внутриаартериальное введение озонсодержащего физиологического раствора по методике Сельдингера, способствует снижению уровня гликемии и оказывает положительный лечебный эффект на результаты комплексного лечения данной категории больных. Стимуляция функциональной активности макрофагов под влиянием озона, а также наличие деструктивных изменений в таких клетках без некротизирующих повреждений может быть объяснено включением механизма апоптоза, как положительного фактора в регуляции местного гомеостаза на завершении воспалительной (экзудативной) фазы раневого процесса.



**Ключевые слова:** Сахарный диабет, озонотерапия, синдром стопы диабетика, апоптоз.



**Topicality.** One of the most typical clinical-morphological manifestations of diabetes mellitus (DM) is microangiopathy – a generalized lesion of all the areas of the microcirculatory flow, capillaries and post-capillary vessels first of all [4, 58-69; 1, 19-22; 3, 1-19]. Hemocirculatory disorders of the lower limb distal parts occurring under those conditions result in pathological complex of symptoms under the common notion “diabetic foot syndrome” (DFS). The WHO defines this term as a complicated complex of morphological and functional changes in foot associated with neuropathy and circulatory disorders of a various severity occurring due to diabetes mellitus [1, 19-22]. DFS develops in 30-80% of patients suffering from diabetes mellitus complicated by necrotic suppurative lesions of the foot in 30-70% [1, 19-22]. In 45-52% of patients with diabetes mellitus this complication causes the loss of resistibility of the lower limbs [1, 19-22].

**Objective:** to evaluate clinically the efficacy of application of the systemic and local ozone therapy in patients with ischemic-gangrenous form of DFS and to study the dynamics of blood sugar changes after prolonged intra-arterial injection of ozone-containing physiological saline with examination of ultrastructural changes of mononuclear macrophages in the focus of inflammation after local application of ozonized physiological saline.

**Materials and methods.** To control the blood sugar level in addition to the standard detection of blood sugar the express-method was used: medical tester “Glucofort-II”, PB “Norma”, Kyiv, supplied with indicator strips “Hemoplan”.

Doppler examination by means of “Super Doplex” (Great Britain) with the installed 7,5 MHz sensor was used to detect the degree of atherosclerotic vascular lesion of the lower limbs. X-ray examination of the affected foot was made to find osteomyelitis lesion and its spread. The fragments of tissue from the wound surface were studied by means of electronic-microscopic examination with their fixation in 2,5% solution of glutaraldehyde on phosphate buffer (pH – 7, 2-7,4) and fixation was

finished in 1% OsO<sub>4</sub> solution. The material was dehydrated in alcohols of increasing concentrations and placed into araldite.

In the process of dehydration the morphological structures were contrasted with a concentrated solution of uranyl acetate, and with lead citrate – on the sections.

The sections 40-60 nanometers thick were obtained on the ultratome УМТП-3 and examined under the electron microscope ТЕСЛА БС-500.

**Results and discussion.** 105 patients with DFS were observed during the period from 2012 to 2015 in the clinical hospital including 62 men (59,04%) and 43 (40,95%) women. The patients were divided into two groups. The main group included 53 (50,47%) patients, and the control group 52 (49,52 %) patients with diabetic foot syndrome. The treatment of the control group of patients consisted of a standard common complex used in case of DFS. Mixed clinical form of diabetes mellitus (DM) prevailed among the patients.

The majority of the patients (84 individuals) were at the age of 65-74 (80 %). Distribution of the patients according to a quantitative and age content was identical and did not differ reliably >0,05 ( Table №1).

**Table №1.** Distribution of patients in the main and control groups

Group of patients	n	Age (M±m)
Main	53	69 ± 1,2
Control	52	68± 1,5
P		>0,05

Note:

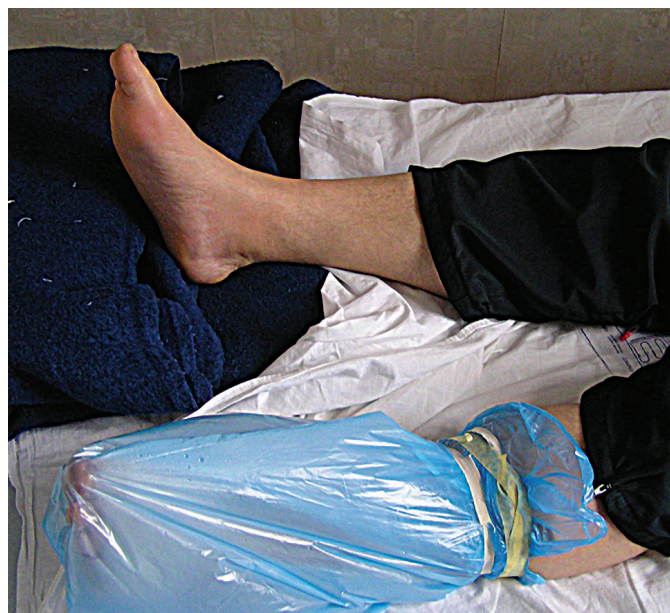n – number of patients.

By the degree of ischemia of the afflicted limb the main and control groups did not differ much (p>0,05). The indices of ischemic definiteness of the lower limbs were similar.

IV degree of definiteness of this complication prevailed among all the hospitalized patients included in the main and control groups. Thus, the main group contained 28 (26,66 %) patients with this pathology, and in the control group there were 26 (24,76 %) of them respectively. General number of the observed patients in both groups was 54 (51,42 %). III degree of ischemia was found in the main group in 15 (14,28 %) patients, and in the control group – in 12 (11,43 %), with the total number of 27 patients (25,71%). II degree of ischemia was detected in 24 patients (22,85 %) without considerable differences in its quantitative content in the main (13 patients – 12,38%) and control groups (11 patients 10,47 %). All the patients of the main group (53 patients – 50,47 %) in addition to the standard therapy similar to that from the control group received prolonged intra-arterial injection of the ozone physiological saline (OPS) by Seldinger method with catheterization of the femoral artery.

At the same time, the above mentioned complex of therapeutic measures in the main group of patients was added by the local action of ozone due to the application of "ozone boot" method (Fig. 1). Clothes were removed from the leg with the signs of locally detected trophic changes on the foot or necrotic suppurative process. After preliminary sanitization of the leg with antiseptic means (3% hydrogen peroxide solution and 0,02 % decasan solution) it is placed in the ozone-containing boot.

The gas concentration in a formed closed space was 15 – 40 mcg/ml. Duration of ozone therapy was 45 minutes, it was performed every day in combination with intra-arterial injection of ozone physiological saline (OPS) in the dose of 200 ml. Infusion was given by means of an infusomat or specially designed for this procedure rack.



**Fig. №1.** Application of "ozone boot" in patients with ischemic-gangrenous form of DFS

Ozone concentration in the solution infused was 2,5-3,0 mg/L and it was injected at the rate of 40-60 drops per minute. The total amount of procedures given to patients was from 6 to 15 depending on the dynamics of the disease and local changes in the place of foot lesion in ischemic-gangrenous form of DFS.

To control the blood sugar level dynamically in addition to the standard detection of blood sugar the express-method was used: medical tester "Glucofort-II", PB "Norma", Kyiv, supplied with indicator strips "Hemoplan".

The efficacy of a comprehensive treatment was evaluated clinically, cytologically and by the results of surgical treatment directed to maximally economical variants of surgery in order to preserve support function of the limb.

With the purpose to make the study more objective the dynamics of blood sugar level in the main group of patients was measured before and after intra-arterial injection of OPS. Similar examinations were made in the control group without prolonged intra-arterial injection

of the ozone physiological saline.

After admission to the hospital all the patients underwent general blood count, urine analysis, urine test on acetone. The following day bilirubin, ALT, AST, urea, creatinine and coagulogram tests were made. The examinations were made according to the common methods. Blood sugar test was detected on the apparatus «Glucofort». On the 7<sup>th</sup> day after a comprehensive treatment was performed the following dynamics of blood sugar changes was detected in the main and control groups in the following time periods: at 8 a.m., 2 p.m., and 6 p.m. of a daily examination of blood sugar.

**Table №2.** Dynamics of changes of the blood sugar level after a prolonged intra-arterial injection of OPS made on the 7<sup>th</sup> day of in-patient treatment of patients with DFS (till 6 p.m.)

Distribution of blood sugar by the time in the groups of patients observed	8 a.m.	2 p.m.	6 p.m.
Main group	9,0 ± 3,3 mmol/L	8,4 ± 3,0 mmol/L	9,2±3,0 mmol/L
Control group	8,8 ± 4,3 mmol/L	9,4 ± 3,3 mmol/L	9,5±3,3 mmol/L
P	>0,05	<0,05	>0,05

Note: P- statistical probability

Changes of the blood sugar level in the patients observed are indicative of the fact that among the patients from the main and control groups this value before the beginning of the procedure remains approximately on the same level and does not show a reliable difference in the control and main groups (>0,05). After a prolonged intra-arterial injection of OPS the patients from the main group presented a reliable difference between these values (<0,05) (Table 2). Hereafter, blood sugar level in both groups observed improved with the tendency to its more distinct decrease in the main group.

This fact is indicative of certain prospects of application of a prolonged intra-arterial injection of OPS in patients with diabetic foot syndrome and promotes further study of direct and remote consequences of this method to treat DFS.

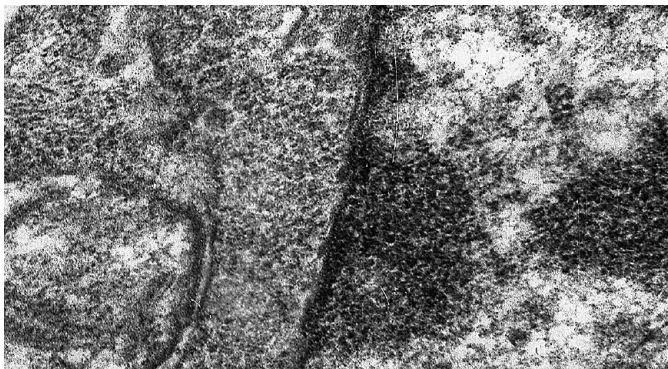
The results of clinical studies conducted found that patients who underwent ozone therapy after 1-2 procedures noted pain reduction more considerably as compared to those from the control group where this method of treatment was not applied. The patients from the main group noted quicker regression of swelling, infiltration and hyperemia around the wound. After 3-4 procedures the body temperature decreased, the values of blood and urine tests improved, tachycardia relieved, sleep and appetite improved.

In the control group these values became stable only on the 12-14<sup>th</sup> days of in-patient treatment. In 10 patients, inflammatory process regressed to the level of phalanges of the foot transforming into dry gangrene. It enabled to perform economic amputations.

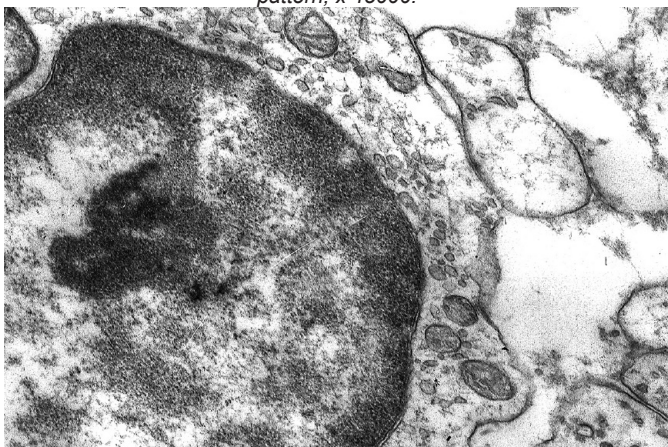
The examinations of macrophage ultrastructure with ozone therapy performed are indicative of the role of oxygen allotropic form (O<sub>3</sub>) as a stimulating factor on their functional activity. It also promotes favourable elimination of these cells mainly due to genetically programmed cellular death (apoptosis) possessing a considerable importance in regulatory mechanisms of inflammatory processes.

Frequently under effect of ozone therapy (as compared to the control group) certain cells were found that remained on different stages of apoptosis. In addition to initial signs a full-scaled phase of this process could be noted with detected condensation of the remains of the nucleus and cellular organelles with initial manifestations of the formation of body apoptosis.

The figures below demonstrate consolidation of the cytoplasm and nuclear membrane with the areas of chromatin condensation available and clearing of the cellular nuclear matrix, and condensation of chromatin, consolidation and homogenization of macrophage nucleus.



**Fig.2.** Consolidation of the cytoplasm and nuclear membrane with the areas of chromatin condensation available and clearing of the cellular nuclear matrix typical for cellular apoptosis. Electron-diffraction pattern, x 45000.



**Fig.3.** Condensation of chromatin, consolidation and homogenization of macrophage nucleus. Electron-diffraction pattern, x 25000.

As we did not make immunohistochemical examinations of apoptosis, the percentage of apoptotically changed cells was not calculated. Although these kinds of cells were often found in the specimens. Mitochondrial way of apoptosis activation was registered, when in spite of availability of destructive changes in the cells mitochondria preserve their activity.

In addition, the signs of a decreased synthesis of structural proteins were found with ozone therapy in destructively changed macrophages: diminution of the cellular nucleus size with absent granular component in it, a small number of free ribosomes and polysomes, which is also typical for a programmed death of the cell.

Stimulation of functional activity of macrophages under ozone effect as well as availability of destructive changes in the cells without necrotizing lesions can be explained by the involvement of apoptosis mechanism as a positive factor in the regulation of local homeostasis on the final inflammatory (exudative) phase of a wound process.

#### Conclusions:

1) The patients of the main group who received OPS injections in addition to the standard treatment were found to demonstrate quicker normalization of the blood sugar level as compared to the patients from the control group.

2) Application of the regional prolonged ozone therapy in a comprehensive treatment of DFS improves clinical signs, stabilizes indices of carbohydrate metabolism and stimulates metabolic and bioenergetic processes in the body of patients with DFS.

3) Stimulation of the macrophage functional activity under ozone effect as well as availability of destructive changes in the cells without necrotizing lesions can be explained by involvement of apoptosis mechanism as a positive factor in the regulation of local homeostasis on the final inflammatory (exudative) phase of a wound process.

**Prospects of further studies.** The results obtained prove reasonability and determine further necessity to conduct exploratory new research in the treatment of diabetic foot syndrome with application of factors with physical and biological effect on activation of reparation process in the wounds of patients with DFS. The study performed is indicative of such a possibility proving substantiated enlargement of indications to perform organ-preserving surgery under these conditions.



#### ЛІТЕРАТУРА

1. Липин А.Н. Неинвазивные способы оценки нарушений периферического кровообращения у больных с диабетическими гангренами / А.Н. Липин // Стационарозамещающие технологии. Амбулаторная хирургия. – 2012. – № 2. – С. 16-19. – с.19-22.
2. Ляпис М.О. Синдром стопи діабетика / М.О. Ляпис, П.О. Герасимчук. – Тернопіль: Укрмедкнига, 2001. – 276 с.
3. Шаповал С.Д. Хірургічна класифікація та алгоритм лікування ускладненого синдрому діабетичної стопи: Методичні рекомендації / С.Д. Шаповал; М-во охорони здоров'я України, Укрмедпатентінформ МОЗ України. – К.: Б.в, 2012. – 19 с.
4. Шлапак І.П. Цукровий діабет: погляд з позиції лікаря-анестезіолога: Навч. посібник. / І.П. Шлапак, О.А. Галушко. – Київ: Книга-плюс, 2010. – 160 с.

#### REFERENCES:

1. Lipin A.N. Neinvazivnye sposoby ocenki narushenij perifericheskogo krovoobrashcheniya u bol'nyh s diabeticheskimi gangrenami / A.N. Lipin // Stacionarozameshchayushchie tekhnologii. Ambulatornaya hirurgiya. – 2012. – № 2. – S. 16-19. – s.19-22.
2. Lyapis M.O. Sindrom stopi diabetika / M.O. Lyapis, P.O. Gerasimchuk. – Ternopil': Ukrmedkniga, 2001. – 276 s.
3. SHapoval S.D. Hirurgichna klasifikaciya ta algoritm likuvannya uskladnenogo sindromu diabetichnoi stopi: Metodichni rekomendacii / S.D. SHapoval; M-vo ohoroni zdorov'ya Ukraini, Ukrmedpatentinform MOZ Ukraini. – K.: B.v, 2012. – 19 s.
4. SHlapak I.P. Cukrovij diabet: poglyad z pozicii likarya-anesteziologa: Navch. posibnik. / I.P. SHlapak, O.A. Galushko. – Kiiv: Kniga-plyus, 2010. – 160 s.