

# КЛІНІЧНА АНАТОМІЯ ТА ОПЕРАТИВНА ХІРУРГІЯ

**Том 22, № 2 (82)**  
**2023**

Науково-практичний медичний журнал  
Видається 4 рази на рік  
Заснований в квітні 2002 року

**Головний редактор**  
Слободян О.М.

**Почесний головний редактор**  
Ахтемійчук Ю.Т.

**Перший заступник  
головного редактора**  
Іващук О.І.

**Заступник головного  
редактора**  
Ковальчук О.І.

**Відповідальні секретарі**  
Товкач Ю.В.  
Бойчук О.М.

**Секретар**  
Лаврів Л.П.

**Редакційна колегія**

Андрієць О.А.

Бербець А.М.

Білоокий В.В.

Боднар О.Б.

Булик Р.Є.

Давиденко І.С.

Максим'юк В.В.

Олійник І.Ю.

Польовий В.П.

Проняєв Д.В.

Сидорчук Р.І.

Хмара Т.В.

Цигикало О.В.

Юзько О.М.

Засновник і видавець: Буковинський державний медичний університет МОЗ України  
Адреса редакції: 58002, пл. Театральна, 2, Чернівці, Україна

URL: <http://kaos.bsmu.edu.ua/>;  
E-mail: [cas@bsmu.edu.ua](mailto:cas@bsmu.edu.ua)

## РЕДАКЦІЙНА РАДА

Білаш С. М. (Полтава), Бойко В. В. (Харків), Вансович В. Є. (Одеса), Вовк О. Ю. (Харків), Гнатюк М. С. (Тернопіль), Головацький А. С. (Ужгород), Гумінський Ю. Й. (Вінниця), Гунас І. В. (Вінниця), Дзюбановський І. Я. (Тернопіль), Каніковський О. Є. (Вінниця), Катеренюк І. М. (Кишинів, Молдова), Кошарний В. В. (Дніпро), Кривко Ю. Я. (Львів), Ляховський В. І. (Полтава), Масна З. З. (Львів), Матешук-Вацеба Л.Р. (Львів), Небесна З. М. (Тернопіль), Пархоменко К. Ю. (Харків), Пастухова В. А. (Київ), Півторак В. І. (Вінниця), Пикалюк В. С. (Луцьк), Попадинець О. Г. (Івано-Франківськ), Россі П. (Рим, Італія), Савва А. (Яси, Румунія), Салютін Р. В. (Київ), Сікора В. З. (Суми), Суман С. П. (Кишинів, Молдова), Топор Б. М. (Кишинів, Молдова), Трофімов М. В. (Дніпро), Федонюк Л. Я. (Тернопіль), Філіпоу Ф. (Бухарест, Румунія), Чемерис О. М. (Львів), Черно В. С. (Миколаїв), Шаповал С. Д. (Запоріжжя), Шепітько В. І. (Полтава), Шкарбан В. П. (Київ).

## EDITORIAL COUNCIL

Anca Sava (Yassy, Romania), Boyko V. V. (Kharkiv), Chemeris O. M. (Lviv), Dzyubanovsky I. Ya. (Ternopil), Florin Filipoiu (Bucureshti, Romania), Pellegrino Rossi (Roma, Italy), Suman Serghei (Kishinev, Moldova), Bilash S.M (Poltava), Vovk O. Yu. (Kharkiv), Gnatyuk MS (Ternopil), Golovatsky A. C. (Uzhgorod), Guminsky Yu. Y. (Vinnitsa), Gunas I. V. (Vinnytsya), Kanikovsky O. Ye. (Vinnytsia), Kateryenyuk I. M. (Kishinev, Moldova), Kosharnyi V. V. (Dnipro), Krivko Yu. Ya. (Lviv), Liakhovsky V. I. (Poltava), Masna Z. Z. (Lviv), Mateshuk-Vatseba L.R. (Lviv), Nebesna Z. M. (Ternopil), Parkhomenko K. Yu. (Kharkiv), Pastukhova V. A. (Kiev), Pivtorak V. I. (Vinnytsia), Pikalyuk V. S. (Lutsk), Popadynets O. H. (Ivano-Frankivsk), Salutin R. V. (Kiev), Shapoval C. D. (Zaporizhzhia), Sikora V. Z. (Sumy), Topor B. M. (Chisinau, Moldova), Fedonyuk L. Ya. (Ternopil), Chernov V. C. (Nikolaev), Shepitko V. I. (Poltava), Skarban V. P. (Kiev), Trofimov M. V. (Dnipro), Vansovich V. Ye. (Odesa).

**Свідоцтво про державну реєстрацію –  
серія КВ № 6031 від 05.04.2002 р.**

**Журнал включений до баз даних:**

**Ulrich`s Periodicals Directory, Google Scholar, Index Copernicus International,  
Scientific Indexing Services, Infobase Index, Bielefeld Academic Search Engine,  
International Committee of Medical Journal Editors,  
Open Access Infrastructure for Research in Europe, WorldCat,  
Наукова періодика України**

---

**Журнал «Клінічна анатомія та оперативна хірургія» –  
наукове фахове видання України**

**(Постанова президії ВАК України від 14.10.2009 р., № 1-05/4), перереєстровано наказом  
Міністерства освіти і науки України від 29 червня 2021 року № 735 щодо включення  
до переліку наукових фахових видань України, категорія «Б»,  
галузь науки «Медицина», спеціальність – 222**

---

Рекомендовано вченою радою  
Буковинського державного медичного університету МОЗ України  
(протокол № 13 від 25.05.2023 року)

ISSN 1727-0847

**Klinična anatomiâ ta operativna hirurgiâ (Print)  
Clinical anatomy and operative surgery**

ISSN 1993-5897

**Klinična anatomiâ ta operativna hirurgiâ (Online)  
Kliničeskaâ anatomiâ i operativnaâ hirurgiâ**

© Клінічна анатомія та оперативна хірургія, 2023

UDC 616.716.4-091

DOI: 10.24061/1727-0847.22.2.2023.14

**A. P. Oshurko, N. I. Yaremchuk\*, I. Yu. Oliinyk\*\*, I. S. Makarchuk\*, V. V. Sukhliak\*\*\*, T. M. Kerimova\*\*\*, O. O. Pompi\*\*\*, E. S. Pompi\*\*\***

*Departments of Surgical Dentistry and Maxillofacial Surgery (Head – Prof. N. B. Kuzniak); \*of Histology, Cytology and Embryology (Head – Prof. O. V. Tsyhykalo); \*\*of Pathological Anatomy (Head – Prof. I. S. Davydenko) Bukovinian State Medical University», Chernivtsi, Ukraine; \*\*\*Department of Dentistry (Head – Assist. T. M. Kerimova) of State Establishment «Luhansk State Medical University» of the Ministry of Health of Ukraine, Rivne, Ukraine.*

## **SIGNIFICANCE OF VARIABILITY OF ANATOMICAL AND TOPOGRAPHIC FEATURES OF THE MANDIBULAR CANAL(S) IN CLINICAL DENTISTRY**

### **ЗНАЧЕННЯ ВАРІАНТНОСТІ АНАТОМО-ТОПОГРАФІЧНИХ ОСОБЛИВОСТЕЙ КАНАЛУ (КАНАЛІВ) НИЖНЬОЇ ЩЕЛЕПИ У КЛІНІЧНІЙ СТОМАТОЛОГІЇ**

---

**Резюме.** У даній роботі представлено аргументи застереження щодо можливого ятрогенного впливу під час проведення одонтологічних чи реконструктивних оперативних втручань на зубо-щелепній системі, а також урахування морфологічної варіантності та топографії каналу (каналів) нижньої щелепи, зі збереженням функціональності його (їх) морфологічних структур.

Мета дослідження полягає в обґрунтуванні необхідного розуміння особливостей морфологічних варіантів та прокладання каналу (каналів) нижньої щелепи, для збереження морфо-функціональних властивостей його (їх) структур, під час проведення стоматологічних консервативно-хірургічних втручань.

Матеріал і методи. Проведений скринінг 1000 цифрових сегментарних записів рентгенологічних досліджень нижньої щелепи людини віком від 25-75 років та виявлено 58 із них, що відображають ятрогенний вплив на її позакореневі морфологічні структури.

Результати досліджень та їх обговорення. Одонтологічна ятрогенність характеризується двома патогенетичними ознаками впливу на периапікальні та прилеглі морфологічні утворення через її механічну й тривалу хімічну дію. Під час механічної дії, першочерговим патологічним проявом є ішемія, у даному випадку нервово-судинного пучка, з різним ступенем його ушкодження, що надалі відображатиметься на зворотному (власному) чи незворотному, або ж умовно зворотному (анастомозуючому) відновленні. У випадку хімічної дії – спостерігають прояви деструктивних змін із прогресуючим ступенем некрозу, залежно від походження та концентрації етіологічного чинника, що в більшості випадків набувають незворотній характер. Патологічні процеси та атрофія кісткової тканини нижньої щелепи, зумовлена втратою жувальної групи зубів, знижують діагностичну диференціацію анатомо-топографічних особливостей каналу (каналів) нижньої щелепи.

Висновки. Нерозуміння індивідуальних анатомічних варіантів та топографії каналу (каналів) нижньої щелепи, під час проведення рентгенологічних досліджень з метою планування стоматологічних оперативних втручань, призводить до пошкодження його морфологічних структур. Будь-яка травматизація нервово-судинного пучка, що прокладається у каналі (каналах) нижньої щелепи виражається пропріорецептивними розладами на ділянках його іннервації, першочергово, та запально-резорбційними процесами, через порушення їх живлення. Ступінь ятрогенності залежить від агресивності патогенетичного чинника та сумарної дії у часі, а також від морфології каналної системи щелепи, яка може взяти на себе функцію «відносної компенсації».

**Ключові слова:** канал нижньої щелепи, комп'ютерна томографія, атрофія кісткової тканини, нижня щелепа.

---

Traditionally, interpreting scientific research problems is easier to understand if their justification is comprehensively evidence-based. Many authors

cite original studies as an example of rehabilitation of patients with the loss of not only the masticatory teeth but also the bone base due to oncological

processes and their consequences. However, they are careful about preserving the anatomical trophism and proprioception of the jaw system [1].

We aim to present arguments for warning of possible iatrogenic effects during odontological or reconstructive surgical interventions on the dental system, taking into account the morphological variation and topography of the mandibular canal(s), which are presented in the works [2-4], while maintaining the functionality of its (their) morphological structures.

After all, the development of practical medicine and the availability of high-tech techniques and methods of rehabilitation of primarily toothless patients by doctors have become a challenge to reduce side causal or functional disorders after their implementation on the human dental system.

Solving the tasks of this problem becomes possible with a perfect understanding of modern diagnostic programs with vast optional capabilities of Computed Tomography of the maxillofacial region [5, 6]. The minimally invasive nature of X-ray diagnostic procedures, the efficiency and objectivity of their analysis, and the reproduction of 3D reconstruction models inspire research confidence, which is also confirmed by the works of foreign authors [7-9].

We have proved [10, 11] not only morphological variation but also quantitative characteristics that are becoming fundamental in Ukrainian science and are already being implemented in clinical practice. These clarifications will contribute to properly rehabilitating patients with bone atrophy complicated by topographic and anatomical features of the mandibular canal system while preserving the function of critical morphological structures in them.

**The aim of the study** is to substantiate the iatrogenic effect, due to the lack of clinical analysis of possible individual variants of the anatomical and topographic features of the mandibular canal (canals) and their importance in the rehabilitation of dental patients, to preserve the morphological and functional properties of its (their) structures during conservative surgical interventions.

**Research methods.** After an initial non-selective screening of 1000 digital records, radiovisiography of fragments of the lower jaw of patients aged 25-75 years who underwent counseling and subsequent treatment in the clinical training base of the medical center «Dentist», 58 patients with direct signs of iatrogenic influence on the periapical tissues of teeth and seven patients with damage to the morphological structures of the mandibular canal were identified, which was confirmed on computed tomography cone-digital images scanned by the Vatech PaX-I 3D Green extra-oral radiography system with a scan size range of 16 x 9 cm, a focal spot 0.5 mm (IES60336) grayscale 14 Bit with a size of 0.2/0.3 voxels.

3D reconstruction models were recreated using the standardized X-ray diagnostic software Ez3D-I Original ver.5.1.9.0, to visualize multimodal and multidimensional images presented as individual results of their research.

**Bioethical standards.** This work was carried out in accordance with the concluded agreement on scientific cooperation between the Departments of Surgical Dentistry and Maxillofacial Surgery, Pathological Anatomy and Histology, Cytology and Embryology of Bukovinian State Medical University and the medical center of the private enterprise Dental Services Center «Dentist» for 2021-2026 from September 29, 2021.

X-ray examinations were conducted after patients provided and signed informed consent to their participation in research in compliance with the main provisions of the GSP (1996), the Council of Europe Convention on human rights and Biomedicine (dated 04.04.1997), World Medical Association Declaration of Helsinki: ethical principles for medical research involving human subjects (1964-2013), current laws of Ukraine and approved by the decision of the Commission on biomedical ethics of Bukovinian State Medical University (Protocol No. 2 of 21.10.2021).

The work is a fragment of the initiative research work of the Department of Histology, Cytology and Embryology of Bukovinian State Medical University «Structural and functional features of tissues and organs in ontogenesis, patterns of variant, constitutional, gender, age and comparative human morphology», state registration number 012IU110121.

**Research results and their discussion.** Any therapeutic or surgical effect on the body has the character of relative or direct iatrogenicity. The most common manifestations are the «consequences» of post endodontic treatment of the root canals of teeth and reconstructive surgical interventions, during the rehabilitation of patients with loss of the masticatory teeth in the lower jaw, due to the lack of preliminary diagnosis or proper skills of the clinician (fig. 1).

Due to its mechanical and long-term chemical action, the iatrogenicity is characterized by twofold pathoetiological signs of influence on periapical and adjacent morphological formations. During mechanical action, the primary pathological process is ischemia, in this case of the neurovascular bundle, with varying degrees of damage, which will later be reflected in the reversible or irreversible, or conditionally reversible (anastomosing) recovery. Under chemical action, the primary pathological process is the manifestation of destructive changes with a progressive degree of necrosis, depending on the origin and concentration of the etiological factor, which in most cases, becomes irreversible.

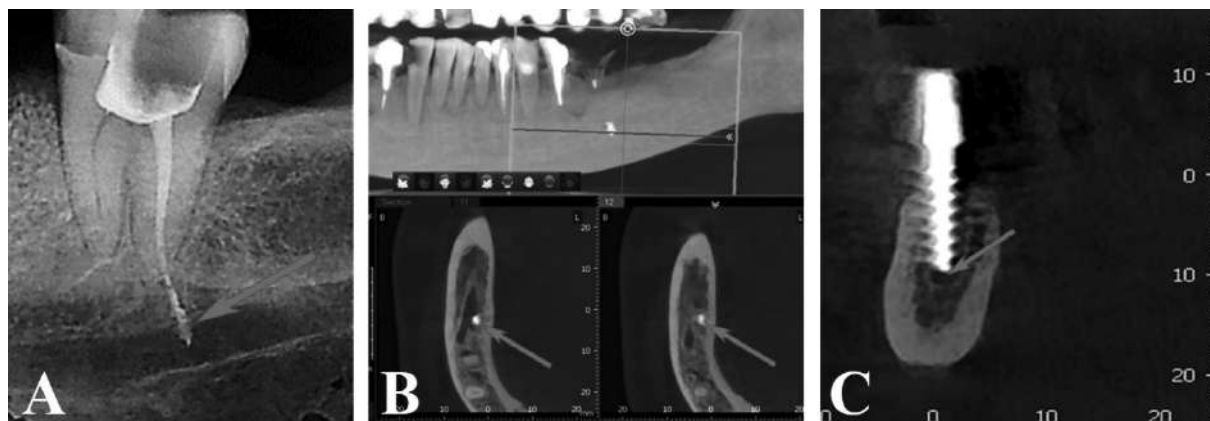


Fig. 1. A) removal of the filling (obturation) material outside the periapical tissues by pushing it into the space of the mandibular canal; B) partial obturation of the lumen of the mandibular canal, on the right side, in the area of the furcation branch; C) partial obturation of the lumen of the mandibular canal with an implant

The most threatening condition is bilateral traumatization of the main morphological structures in the mandibular canals during preparation or, in fact, compression implantation. After all, the primary nutrition and innervation of the solid base of the lower jaw occur by «highways» that are laid through its canal(s). When obturation occurs, or when implants create compression

pressure on the lumen of the canal, not only ischaemia but also relative stasis is caused, with the subsequent development of a cascade of pathophysiological reactions.

The longer the effect, the more pronounced it leads to aggressive, destructive, mostly irreversible pathological processes, even in areas where their localization is unique (fig. 2).

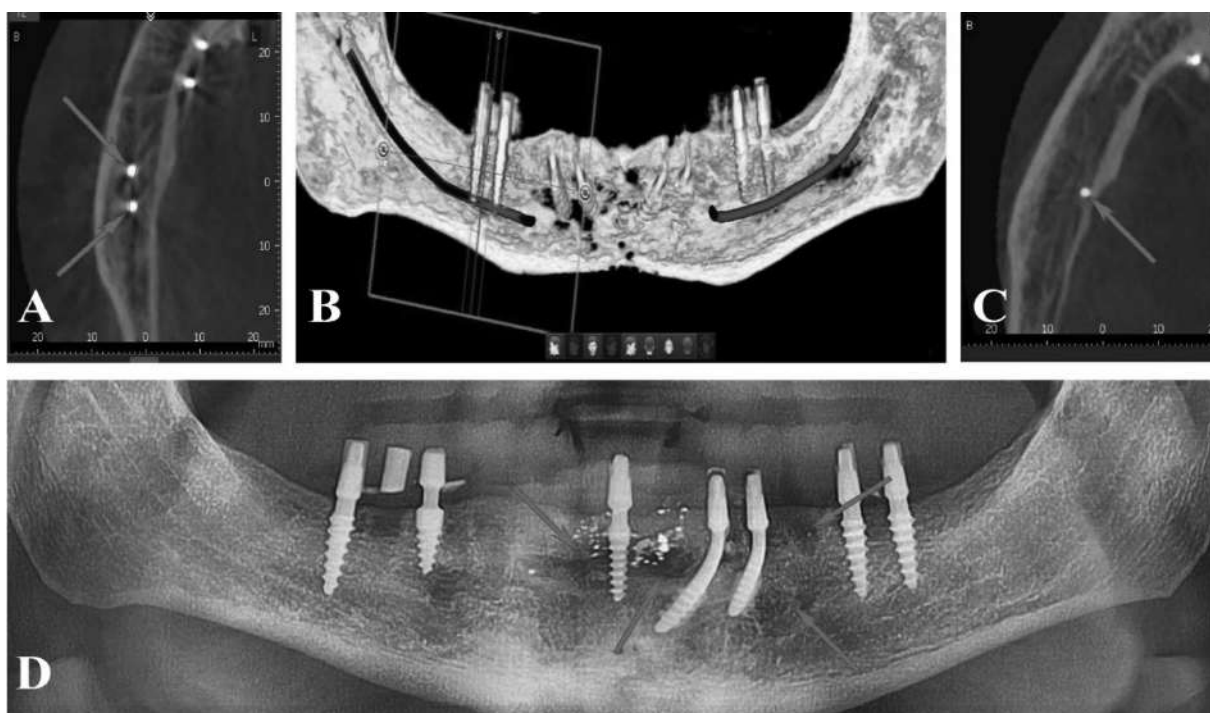


Fig. 2. CT image of the lower jaw (LJ) presented on coronal (B) and axillary (a – right side, C – left side) sections in the format of 3D reconstruction models with the reflection of iatrogenic effects on the morphological structures of the mandibular canal; D) pathological foci with different degrees of bone destruction (panoramic radiography after removal of implants on the right side)

Therefore, paying due attention to a detailed radiological examination, with an understanding of the interpretation of the possible variant anatomy of the mandibular canal(s) and its (their) laying, will protect against possible negative consequences of trauma to

the neurovascular complex during odontogenic or reconstructive interventions.

Traumatization of the neurovascular bundle laid in the mandibular canal(s) is expressed by proprioceptive disorders in the areas of its

innervation, primarily inflammatory-resorption processes, due to a violation of their nutrition. Of course, the degree of iatrogenicity depends on the aggressiveness of the pathoetiological factor and the summation of its action over time, as well as on the morphology of the mandibular canal system, which can take on the function of «relative compensation». However, in order to comply with the principles of biological expediency during restorative or reconstructive surgical interventions and even simple odontogenic treatment, at first glance, it is necessary to clearly understand variant anatomy and the topographical features of the mandibular canal(s) with partial, complete loss of teeth or its laying – in people with a preserved dentition, which has its differences.

Our previous works present variant anatomy of the canal as the central tunnel and its bifurcation and trifid modifications [10]. Also, its topographic variability in bone atrophy caused by the loss of the masticatory teeth is detailed [11], which has become an anatomical indicator for understanding and choosing methods and techniques for directed bone regeneration or for restoring the function of chewing efficiency by subcortical or basal (bicortical) implantation. Having obtained an appropriate level of knowledge, these studies contributed to the implementation of their results in clinical dentistry, taking into account the complicated topographic features of the mandibular canal(s) with forms of vertical and horizontal bone atrophy and their variants with a high level of lining in the jaw body (fig. 3), or other difficult to differentiate individual manifestations.

Organization of standard operational interventions (fig. 4) implantation, with a simultaneous combination of lateral bone augmentation, fixing

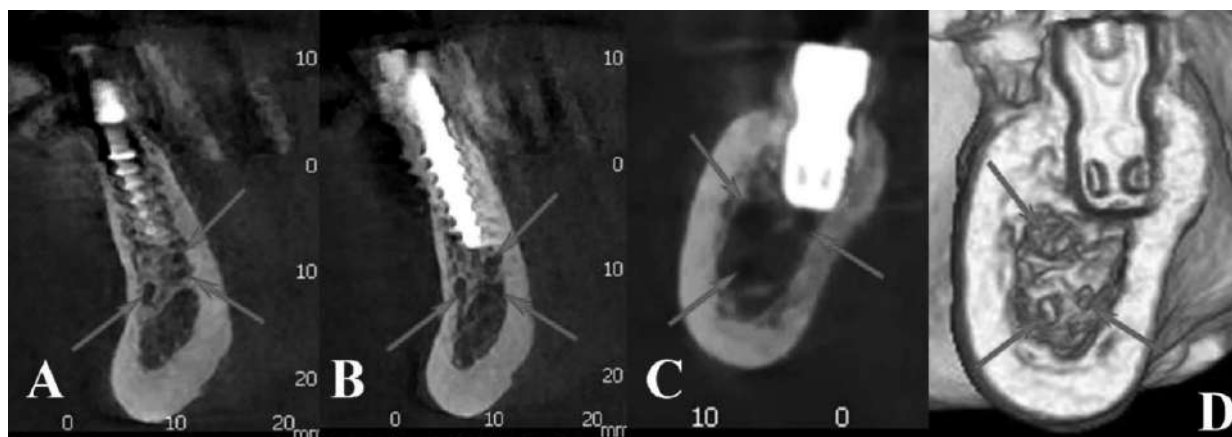
the membranes with cortical core, and even simple endodontic root canal treatment, does not somehow require a clear representation of the anatomical variants and topography of the mandibular canal(s) (fig. 5) [12].

The authors of the scientific publication [13] also focus on the morphological variation of the mandibular canal in the retromolar region with its bifid branching, which has a significant clinical and diagnostic reference point for performing typical, and, for the most part, atypical surgical interventions for a wisdom tooth removal.

Attention is drawn to an entirely new work [14], which interprets the anatomical characteristics of not only the retromolar canal but also presents variants of its bifid and trifid branches in the body of the lower jaw, with a proposal to make changes to the morphological terminology, since the frequency of such manifestations is relatively high.

The American Journal of the Association of plastic surgeons published a paper [15] confirming the importance of understanding the topography of the mandibular canal(s), particularly its exit, to take into account the safe distance during osteoplasty, minimizing iatrogenic postoperative effects.

Researchers of the odontology departments of oral and maxillofacial sciences of the Italian university (Sapienza University of Rome, 00161 Rome, Italy, University of Rome Tor Vergata, 00133 Rome, Italy) [16] indicate the presence of gaps in anatomical educational reference books for students of higher educational institutions, as well as focus the attention of clinicians performing manipulations on the lower jaw on the possible variability of canals and topography with their outlet openings.



*Fig. 3. X-ray postoperative Images: A-B) Models with a vertical form of atrophy and a polycanal system after bicortical implantation are represented by a sagittal section of the toothless segment of the lower jaw; C-D) Models with a horizontal form of atrophy and a polycanal system, after subcortical implantation, are represented by a sagittal section of the toothless segment of the lower jaw*

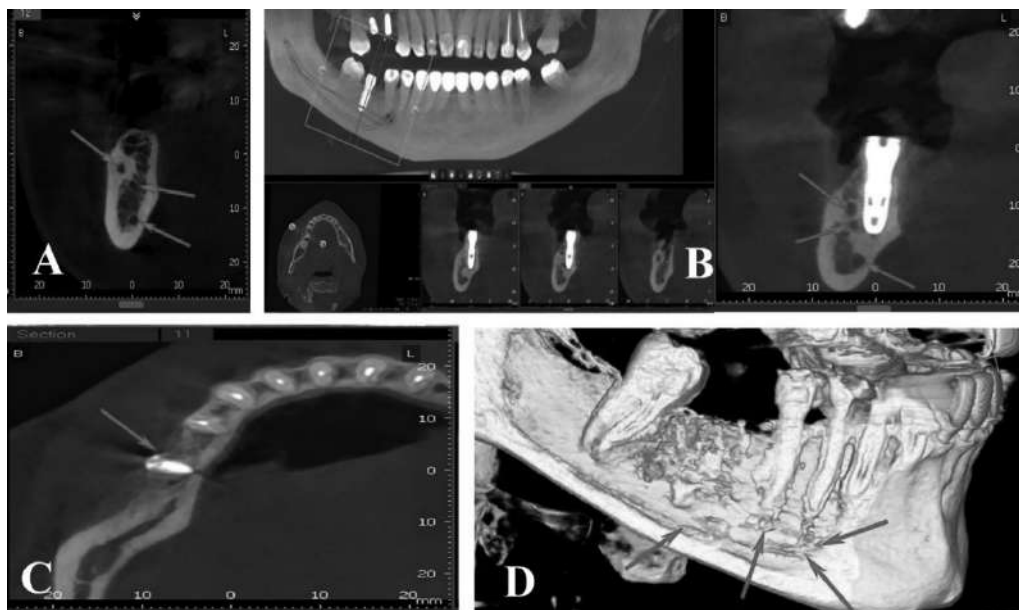



Fig. 4. CT image of the lower jaw: A) sagittal section of the trifold variant of the mandibular canals; B) panoramic image and sagittal sections after subcortical implantation, taking into account the topographic and morphological features of the trifold manifestation of the mandibular canals; C) axillary section of the bicortical fixation of the barrier membrane after lateral augmentation, taking into account the topography of the mandibular canal; D) coronal (frontal) cross-section of a 3D reconstruction model of the mandibular canal system

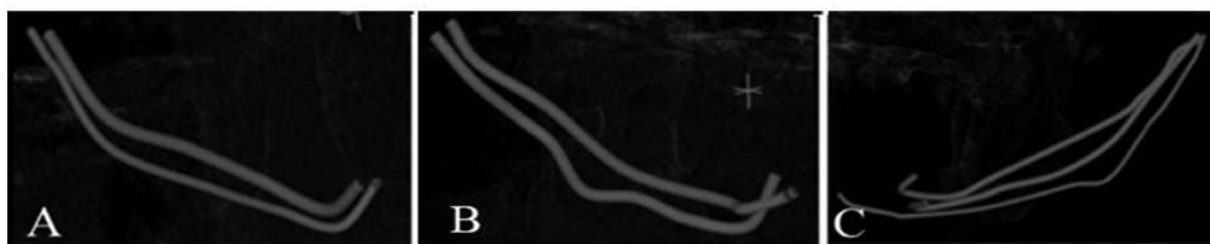
**Anatomical and topographic classification of the mandibular canal, 2022  
(Oshurko AP, Oliinyk IYu & Kuzniak NB):**

**I. By anatomical variation:**

- 1.1. Single-canal type (single-tube – A, bifurcation – B, trifurcation – C)



- 1.2. Polycanal type (two-canal – A and B, multi-canal – C)



**II. By topographic ratio:**

**First class (I-cl, <45 years old):**

- **RMB**, distance from the ridge of the mandibular base to the mandibular canal – 7.2 (= 7.0) mm;
- **BR**, distance from the ridge of the buccal surface to the mandibular canal – 4.8 (= 5.0) mm;
- **LR**, distance from the ridge of the lingual surface to the mandibular canal – 2.9 (= 3.0) mm.

**Second class (II-cl, > 45 years old):**

- **RMB**, distance from the ridge of the mandibular base to the mandibular canal – 8.0 mm;
- **BR**, distance from the ridge of the buccal surface to the mandibular canal – 5.3 mm;
- **LR**, distance from the edge of the lingual surface to the mandibular canal – 3.3 mm.

Note: (= ...) - a sign approaching a specific number.

Fig. 5. Anatomical and topographic classification

At the same time, prolonged delay or clinical restriction due to fear of iatrogenic effects leads to delayed rehabilitation of patients with loss of the masticatory teeth in the lower jaw, and is a direct prerequisite for changes in the vertical dimension of occlusion, causes the acquisition of its variable morphological and morphometric features, leading to an interrelated process of bone atrophy of the cellular part, the body of the mandible, as well as the cortical and trabecular layers of the condylar and coronal processes of the mandible.

**Conclusion.** 1. Manifestations of variation of the mandibular canal(s) and their topography are well diagnosed in the body of the mandible with a preserved dentition. 2. Pathological processes and atrophy of the mandibular bone tissue caused by the loss of the masticatory group of teeth reduce the diagnostic differentiation of the anatomical and topographic features of the mandibular canal(s). 3. The study of individual anatomical variants of the mandibular canal(s) and its

laying is a prerequisite for clinicians to prevent iatrogenic effects on the morphological structures of the canal. 4. Any traumatization of the neurovascular bundle laid in the mandibular canal(s) is expressed by proprioceptive disorders in the areas of its innervation, primarily inflammatory-resorption processes, due to a violation of their nutrition. 5. The degree of iatrogenicity depends on the aggressiveness of the pathoetiological factor and the summation of its action over time, as well as on the morphology of the mandibular canal system, which can take on the function of «relative compensation».

**Prospects for further research.** The prospect of further research is to clarify the frequency of variation of the mandibular canal(s), their morphological and topographic rearrangement (variability), depending on bone atrophy, on toothless human jaws, the study of interrelated processes of bone atrophy as the cellular part, the body of the lower jaw, and the cortical and trabecular layers of the condyle and coronal processes of the lower jaw.

#### Список використаної літератури

1. Gaur V, Doshi AG, Gandhi S. Immediate Prosthetic Rehabilitation of Marginal Mandibulectomy Post Radiation Case by Single-Piece Implant – A Case Report. *Ann Maxillofac Surg.* 2020;10(2):501-6. doi: 10.4103/ams.ams\_260\_20.
2. Miličević A, Salarić I, Đanić P, Miličević H, Macan K, Orihovac Ž, et al. Anatomical Variations of the Bifid Mandibular Canal on Panoramic Radiographs in Citizens from Zagreb, Croatia. *Acta Stomatol Croatia.* 2021 Sep.;55(3):248-55. doi: 10.15644/asc55/3/2.
3. Sirera-Martín Á, Martínez-Almagro-Andreo A. Variantes Anatómicas en el Canal Mandibular en Adultos Jóvenes Mayores de 30 Años. *Int J Morphol.* 2020;38(4):899-902. <https://doi.org/10.4067/S0717-95022020000400899>.
4. Qaid N, Aldilami A, AL-Jawfi K, Shamala A. Prevalence and morphological assessment of bifid mandibular canal using cone beam computed tomography among a group of yemeni adults. *J Indian Acad Oral Med Radiol.* 2021;33(3):242-7. doi: 10.4103/jiaomr.jiaomr\_218\_20.
5. Shan S, Zhong S, Li J, Wang T. Systematic review and meta-analysis of mandibular canal variations on cone beam computed tomography. *Oral Radiol.* 2022;38(4):445-51. doi: 10.1007/s11282-022-00610-5.
6. Nithya J, Aswath N. Assessing the prevalence and morphological characteristics of bifid mandibular canal using cone-beam computed tomography – A retrospective cross-sectional study. *J Clin Imaging Sci.* 2020 May 23;10,30:1-6. doi: 10.25259/JCIS\_67\_2019.
7. Von Arx T, Bornstein MM. The bifid mandibular canal in three-dimensional radiography: morphologic and quantitative characteristics. *Swiss Dent J.* 2021;131(1):10-28.
8. Zhou X, Gao X, Zhang J. Bifid mandibular canals: CBCT assessment and macroscopic observation. *Surg Radiol Anat.* 2020;42(9):1073-9. doi: 10.1007/s00276-020-02489-5.
9. Enderle F, Grill F, Rommel N, Ritschl L, Grandoch A, Wolff KD, et al. Radiographic analysis of the anterior mandible and its anatomical variations using cone-beam computed tomography. *Quintessence Int.* 2022;53(10):874-82. doi: 10.3290/j.qi.b3315007.
10. Oshurko AP, Oliinyk IYu, Kuzniak NB. Variant anatomy of the mandibular canal topography *Вісник морфології.* 2022;28(2):62-8. doi: 10.31393/morphology-journal-2022-28(2)-09.
11. Oshurko AP, Oliinyk IYu, Kuzniak NB. Classification of the topography of the mandibular canal in case of bone atrophy caused by the loss of the masticatory teeth. *Вісник проблем біології і медицини.* 2022;2,2(165):131-5. doi: 10.29254/2077-4214-2022-2-2-165-131-135.



12. Oshurko AP, Oliinyk IYu, Kuzniak NB. Anatomical and topographic classification of the mandibular canal with bone atrophy caused by the loss of the masticatory teeth. *Romanian Journal of Stomatology*. 2022;68(4):160-6. doi: 10.37897/RJS.2022.4.1.
13. Iliescu VI, Cismaş SC, Truţă RI, Gherghiţă OR, Nimigean V, Nimigean VR. Bifid mandibular canal – a case report. *Rom J Morphol Embryol*. 2021;62(2):633-6. doi: 10.47162/RJME.62.2.34.
14. Iwanaga J, Takeshita Y, Matsushita Y, Hur MS, Ibaragi S, Tubbs RS. What are the retromolar and bifid/trifid mandibular canals as seen on cone-beam computed tomography? Revisiting classic gross anatomy of the inferior alveolar nerve and correcting terminology. *Surg Radiol Anat*. 2022;44(1):147-56. doi: 10.1007/s00276-021-02862-y.
15. Lin HH, Denadai R, Sato N, Hung YT, Pai BCJ, Lo LJ. Avoiding inferior alveolar nerve injury during osseous genioplasty: a guide for the safe zone by three-dimensional virtual imaging. *Plast Reconstr Surg*. 2020;146:847-58. doi: <https://doi.org/10.1097/prs.00000000000007160>.
16. Sferlazza L, Zaccheo F, Campogrande ME, Petroni G, Cicconetti A. Common Anatomical Variations of Neurovascular Canals and Foramina Relevant to Oral Surgeons: A Review. *Anatomia*. 2022;1(1):91-106. <https://doi.org/10.3390/anatomia1010010>.

### SIGNIFICANCE OF VARIABILITY OF ANATOMICAL AND TOPOGRAPHIC FEATURES OF THE MANDIBULAR CANAL(S) IN CLINICAL DENTISTRY

**Abstract.** This paper presents arguments about the possible iatrogenic effect during odontological or reconstructive surgical interventions on the dental-maxillary system, taking into account the morphological variability and topography of the mandibular canal(s) while maintaining the functionality of its (their) morphological structures.

**The aim of the study** is to substantiate the necessary understanding of the peculiarities of morphological variants and laying the mandibular canal(s) in order to preserve the morphological and functional properties of its (their) structures during dental conservative and surgical interventions.

**Material and Methods.** The screening of 1000 digital segmental records of X-ray examinations of the human lower jaw aged 25-75 years was conducted, and 58 of them were identified, reflecting the iatrogenic effect on its foliar morphological structures.

**Results and Discussion.** Due to its mechanical and long-term chemical action, odontological iatrogenicity is characterized by twofold pathoetiological signs of influence on periapical and adjacent morphological formations. During mechanical action, the primary pathological manifestation is ischemia, in this case of the neurovascular bundle, with varying degrees of damage, which will later be reflected in the reversible or irreversible, or conditionally reversible (anastomosing) recovery. In the case of chemical action, there are manifestations of destructive changes with a progressive degree of necrosis, depending on the origin and concentration of the etiological factor, which in most cases, becomes irreversible. Pathological processes and atrophy of the mandibular bone tissue caused by the loss of the masticatory group of teeth reduce the diagnostic differentiation of the anatomical and topographic features of the mandibular canal(s).

**Conclusions.** Misunderstanding of individual anatomical variants and topography of the mandibular canal(s) during X-ray examinations to plan dental surgical interventions leads to damage to its morphological structures. Any traumatization of the neurovascular bundle laid in the mandibular canal(s) is expressed by proprioceptive disorders in the areas of its innervation, primarily inflammatory-resorption processes, due to a violation of their nutrition. The degree of iatrogenicity depends on the aggressiveness of the pathoetiological factor and the summation of its action over time, as well as on the morphology of the mandibular canal system, which can take on the function of «relative compensation».

**Key words:** mandibular canal, computed tomography, bone atrophy, lower jaw.

*Відомості про авторів:*

**Ошурко Анатолій Павлович** – доктор філософії, докторант кафедри хірургічної стоматології та щелепно-лицевої хірургії, ЗВО «Буковинський державний медичний університет», м. Чернівці;

**Яремчук Назар Ігорович** – аспірант кафедри гістології, цитології та ембріології ЗВО «Буковинський державний медичний університет», м. Чернівці;

**Олійник Ігор Юрійович** – доктор медичних наук, професор, професор кафедри патологічної анатомії ЗВО «Буковинський державний медичний університет», м. Чернівці;

**Макарчук Ігор Святославович** – аспірант кафедри гістології, цитології та ембріології ЗВО «Буковинський державний медичний університет», м. Чернівці;

**Сухляк Валентина Василівна** – кандидат медичних наук, асистент кафедри стоматології ДЗ «Луганський державний медичний університет», м. Рівне;

**Керімова Тетяна Миколаївна** – асистент кафедри стоматології ДЗ «Луганський державний медичний університет», м. Рівне;

**Помпій Олександр Олександрович** – доцент, доцент кафедри стоматології ДЗ «Луганський державний медичний університет», м. Рівне;

**Помпій Еліна Сергіївна** – асистент кафедри стоматології ДЗ «Луганський державний медичний університет», м. Рівне.

*Information about the authors:*

**Oshurko Anatolii P.** – PhD (Med), Postdoctoral student of the Department of Surgical Dentistry and Maxillofacial Surgery, Bukovinian State Medical University, Chernivtsi;

**Yaremchuk Nazar I.** – Postgraduate Student of the Department of Histology, Cytology and Embryology, Bukovinian State Medical University, Chernivtsi;

**Oliinyk Ihor Yu.** – MD, Professor, Professor of the Department Pathological Anatomy, Bukovinian State Medical University, Chernivtsi;

**Makarchuk Ihor S.** – Postgraduate Student of the Department of Histology, Cytology and Embryology of Bukovinian State Medical University, Chernivtsi;

**Sukhliak Valentyna V.** – Candidate of Medical Sciences, assistant of the Department of Dentistry, SE «Luhansk State Medical University», Rivne;

**Kerimova Tetiana M.** – Assistant of the Department of Dentistry, SE «Luhansk State Medical University», Rivne;

**Pompii Oleksandr O.** – Candidate of Medical Sciences, associate professor of the Department of Dentistry, SE «Luhansk State Medical University», Rivne;

**Pompii Elina S.** – Assistant of the Department of Dentistry, SE «Luhansk State Medical University», Rivne, Ukraine.

Надійшла 10.04.2023 р.

Рецензент – проф. О. І. Годованець (Чернівці)