

ISSN 2504-5660

Eureka



EUREKA:

HEALTH SCIENCES

- Medicine and Dentistry
- Nursing and Health Professions
- Pharmacology, Toxicology
- Pharmaceutical Science
- Veterinary Science
- Veterinary Medicine

Volume 1(1)
2016



EDITORIAL BOARD



SCIENTIFIC JOURNAL

EUREKA: Health Sciences covers the discipline of medical profile and applied disciplines focused on getting the finished product for medicine. Therefore, the authors in their materials should *emphasize areas of application* of their research, always *emphasizing the ability to attract knowledge, aimed at preserving the health from related scientific fields.*

The problems of the following areas:

- conventional western disciplines
- traditional and folk medicine,
- alternative medicine.

EUREKA: Health Sciences publishes 4 types of materials:

- review article,
- progress reports,
- full paper,
- clinical case reports

PUBLISHER OÜ «Scientific Route»

European Union

Editorial office

«EUREKA: Health Sciences»

Narva mnt 7-634, Tallinn, Eesti

Harju maakond, 10117

Tel. + 372 602-7570

e-mail: info@eu-jr.eu

Website: <http://eu-ir.eu>

EDITORS-IN-CHIEF

Iqbal A. Bukhari, *University of dammam, Saudi Arabia*

EDITORS

Talal Aburjai, *University of Jordan, Jordan*

Mohammad R. Ardalan, *Tabriz University of Medical Sciences, Iran*

Evgeni Chumachenko, *France*

Marine Georgiyants, *Kharkiv Medical academy of Postgraduate Education, Ukraine*

Kamyar Ghabili, *James Buchanan Brady Urological Institute, the Johns Hopkins Medical Institutions, Baltimore, Maryland, United States*

Rohit Gundamaraju, *School of Health Sciences, University of Tasmania, Australia*

Mohamed Azmi Ahmad Hassali, *Universiti Sains Malaysia, Malaysia*

A. Heidari, *California South University (CSU), United States*

Rodney P Jones, *Healthcare Analysis & Forecasting, United Kingdom*

Sidharth Mehan, *RITS, SIRSA, India*

Prasanta Kumar Mitra, *Institute of Medical Sciences, India*

Manju Ananthkrishanan Nair, *Department of Oral & Maxillofacial Surgery, Pacific Dental College & Research Center, Pacific Academy of Higher Education & Research University, India*

Janne Seemann, *Aalborg University, Denmark*

Bechan Sharma, *Centre for Biotechnology Nodal Officer, Intellectual Property Rights Cell Chairman, Core Committee-Environmental Science University of Allahabad Allahabad-U.P., India*

Shalini Sharma, *Moksha Publishing House, India*

CONTENT

SOMATO-PSYCHIC DISORDER CLINICAL CASE IN A FEMALE PATIENT WITH MULTINODULAR EUTHYROID GOITER <i>Oksana Tsyganenko</i>	<u>3</u>
CLINICAL CASE – SCLEREDEMA ADULTORUM <i>Liliya Hulei</i>	<u>9</u>
CLINICONEUROLOGICAL AND NEUROPSYCHOLOGICAL ASPECTS OF ACUTE PERIOD OF MILD CRANIAL BRAIN TRAUMA CAUSED BY SHOCK WAVE <i>Volodymyr Korshnyak, Viktor Sukhorukov</i>	<u>14</u>
GENETIC TRIGGERS AND NEUROHUMORAL MESSENGERS OF POSTOPERATIVE INTESTINAL PARESIS, ITS VALUE IN PREDICTION, PREVENTION AND TREATMENT <i>Volodymyr Moskaliuk</i>	<u>19</u>
THE MODERN APPROACH TO THE COMPLEX THERAPY OF DEMODICOSIS <i>Zhanetta Revenko</i>	<u>25</u>
COMPARATIVE CHARACTERISTICS OF THE METHODS OF CHEMODRUGS ADMINISTRATION IN THE TREATMENT OF PATIENTS WITH LOCALLY-ADVANCED BREAST CANCER <i>Igor Sedakov, Vladlena Dubinina, Oleksandr Bondar, Oleg Lukianchuk, Oleksandr Zavoloka</i>	<u>31</u>
MATRIX METALLOPROTEINASE-9 AND INFLAMMATION IN DIFFERENT TYPES OF MULTIPLE SCLEROSIS <i>Nataliya Voloshyna, Vitaliy Vasylovskyy, Tatyana Nehreba, Maksym Chernenko, Viktoriya Vovk</i>	<u>39</u>
THE METHOD OF TREATMENT OF PATIENTS WITH LOCALLY-ADVANCED BREAST CANCER <i>Igor Sedakov, Vladlena Dubinina, Oleksandr Bondar, Oleg Lukianchuk</i>	<u>45</u>
ALCOHOLIZATION IN THE STRUCTURE OF POSTSTRESS MALADJUSTMENT <i>Konstantin Gaponov</i>	<u>51</u>

THE MODERN APPROACH TO THE COMPLEX THERAPY OF DEMODICOSIS

Zhanetta Revenko

*Department of Social Medicine and the Organization of Health Care
Higher State Educational Establishment of Ukraine
«Bukovinian State Medical University»
2 Teatralnaya sq., Chernivtsi, Ukraine, 58002
ozo@bsmu.edu.ua*

Abstract

Demodicosis is one of the most common diseases of the skin. Despite the large number of scientific publications on this issue the question of the etiology and pathogenesis of this disease still remains unresolved and the development of more effective methods of treatment and prevention has not only medical but also social significance as patients preserving the working ability have actually long enough to be on outpatient and even inpatient treatment. In addition the long existence of the rash on the face that is the “business card” leads to the secondary sometimes severe neurotic disorders that results in reducing abilities, isolation, unwillingness to be in a team, family, etc.

We investigated the effect of complex therapy which had been conducted by means of antiparasitic, immunomodulatory, anti-inflammatory and desensitizing drugs in patients with demodicosis, as well as mandatory adjustment of changes in the hepato-pancreato-duodenal system. We examined 109 patients with demodicosis from 18 to 39 years old and 10 healthy individuals of the corresponding age and sex. It was established that the effectiveness of treatment of demodicosis based on the application of albendazole in the complex treatment along with immune-modulating therapy and hepatoprotection increased significantly. There has been a reliable rapid regression of clinical symptoms in most patients with demodicosis.

Keywords: demodicosis, hepato-pancreato-duodenal zone (HPDZ), antiparasitic therapy, acaricidal preparations, delayed-type hypersensitivity (DTH) reactions.

© Zhanetta Revenko

1. Introduction

Demodicosis – a skin disease which can be caused not only by the mite (demodex), but also by the presence of a number of factors: changes in the function of the sebaceous glands in the skin and reduced immunity. It is under these conditions when subcutaneous mite begins to multiply. It is very small, it is particles of mm long (it cannot be seen with your eyes) [1]. Demodex lives on the skin of most people without causing any changes. Demodex often begins multiplying during the puberty period when hormones influence the changes in the composition of sebum and necessary nutrient medium for mite reproduction appears. Multiplying demodex begins to cause inflammation in the skin [2].

Demodicosis is an associated disease in the occurrence of which disturbances in adaptive-protective properties of the body play an important role.

Specific chemotherapy is known to be the leading treatment for parasitic diseases. But very often the course of demodicosis is a constant chronic disease against the background of hepato-pancreato-duodenal system pathology which in turn leads to complications in its course. At disturbances of the immune status of the host even active chemotherapy does not produce any effect or fast reinfection occurs [3]. Therefore a topical treatment alone does not usually produce clinical effect. Furthermore it is not an open secret that the antiparasitic therapy possesses a significant toxic effect on the entire body [4]. Therefore its implementation should be duplicated with the means eliminating the harmful effects of chemotherapy. Side effects and complications of antiparasitic therapy also require the development of special schemes for specific pathogenetic therapy and chemotherapy with the use of complex treatment to eliminate any negative effects.

Thus for the successful treatment of patients with demodicosis one should consider not only the form and stage of the disease but also changes in other organs and systems. Complex treatment should include along with antiparasitic therapy immunomodulatory, anti-inflammatory and desen-

sensitizing ones as well as compulsory correction of changes in the hepato-pankreato-duodenal system, which in its turn will significantly increase the effectiveness of treatment of demodicosis [5].

In the development of the pathological process in demodicosis immunological and immunopathological reactions occupy an important place [6]. Therefore parasitico-genic immunosuppression which produces inhibitory effect on metabolism, enzymatic activity and this hinders the absorption of antiparasitic chemotherapeutic drugs is of a great importance at structural and functional disorders of hepato-pankreato-duodenal zone (HPDZ). Toxic action of antiparasitic drugs, sensitizing effect of mite allergens, autoimmune action of host tissue necrosis products have a negative effect on the HPDZ organs due to cytopathogenic action of chemotherapy and parasites decomposition products.

Apart from that it should be noted that the difficulties in the therapy of demodicosis which is far from being always successful even when using the most effective acaricides are related to the features of the composition of mite coatings. Demodex cuticle consists of three layers (external one is epicuticle, the medium is exocuticle and the internal is endocuticle) and the structure is most developed in females [7]. A characteristic feature of the structure of the cuticle is that in the inner layers of exo- and endocuticles there are no poriferous canals connected with the external medium that is why it can only participate in the water and gas exchange. For this reason the passage of large molecules of exogenous substances in particular of contact acaricides through the demodex cuticle is difficult or even impossible. It is the fact which explains the difficulty in anti-parasitic therapy for demodicosis, the need for long treatment courses and choice of drugs with a minimal size of molecules [8].

Aims. To carry out a study of the clinical efficiency of new antiparasitic drugs and their application in combination with immunomodulatory therapy.

2. Materials and methods

We have examined 109 patients suffering from demodicosis from 18 to 39 years old (including 49 men and 60 women) and 10 healthy individuals of the corresponding age and sex.

All the patients underwent common clinical and laboratory examination as well as immunological studies such as hormonal – we determined adaptive hormones rate (cortisol and insulin) in the blood, leukocyte intoxication index (LII), HPDZ organs were examined too [9].

According to the anamnesis, the duration of illness was as follows: up to 6 months in 6 (6 %) patients, up to 1 year in 19 (17 %) patients, up to 3 years in 28 (26 %) patients, up to 5 years in 33 (30 %) patients, up to 10 years in 15 (14 %) patients, and over 10 years in eight (7 %) patients.

We noticed mostly a chronic course of demodicosis issuing from the lack of effectiveness of conventional treatments.

In most patients the inflammation process was localized on the skin of their face, in some patients it also spread to the neck area, the chest, the back and auricles. It should be noted that only 12 of the 109 patients complained of slight itching and burning in lesions areas; there were not any other subjective complaints. The clinical course in patients with demodicosis was characterized by a strong seasonality, with exacerbation in spring and summer.

In 98 (89.9 %) out of 109 patients with demodicosis we found comorbidities of HPDZ organs and in 86 (79 %) of them intestinal parasitoses (enterobiosis and giardiasis) were detected.

Depending on the severity of disease and its prescription, the patients with demodicosis were divided into three groups. The first group included 43 patients who took antiparasitic drug albendazole as a component of combined therapy. The second group consisted of 48 patients who took antiprotozoal drug ornidazole in the combined therapy and the rest 18 patients with demodicosis took albendazole and ornidazole in the combined therapy. We did not use acaricidal agents with contact action in our study.

3. Results

We defined the following goals while treating demodicosis: to eliminate the infectious agent, to exclude any skin irritative effects, to restore the immunity, to normalize blood circulation, contributing to skin restoration

All the patients underwent combined treatment which included antiparasitic, immunomodulatory, anti-inflammatory and desensitizing therapies, as well as mandatory adjustment of changes

in the hepato-pankreato-duodenal system, which in its turn significantly increased the effectiveness of treatment of demodicosis.

All the patients who received albendazole and ornidazole were quite tolerable to them. None of the patients had any adverse effects or changes in clinical and laboratory findings that could be related to the drug taking.

While treating demodicosis the patients took ornidazole parenterally within 10 days in a dose of 500 mg twice a day.

There were not any side effects. Contraindications: early pregnancy, lactation, patients with affected CNS. Efficiency: 98–99 %.

A drug called albendazole can be chosen for treatment of demodicosis (the first domestic anti-helminthic preparation of albendazole is Aldazole) and it is highly effective in mono and poly-invasions, it has larvicide, ovicide and vermicide action (it affects mature parasites, their eggs and larvae. High therapeutic activity and broad spectrum of albendazole (aldazole) effect is provided through a dual mechanism of the action [10]:

- inhibition of tubulin protein synthesis which leads to a disruption of the cytoskeleton of the parasite;
- inhibition of fumarate hydratase (the main enzyme in the Krebs cycle of the parasite) resulting in the disruption of synthesis and glucose uptake. Both mechanisms of action cause the death of the parasite.

These drugs were administered in case of demodicosis in a dose of 400 mg twice a day for 10 days after meals.

Patients took 2 capsules of “Hepadif” 2–3 times a day regardless of the meal. The capsules should be usually taken in whole with water. If swallowing is difficult the contents of the capsule can be dissolved in 50 ml of juice or water. Clinical and laboratory examination of the patients taking Hepadif showed that their general condition improved much sooner [11]. Their clinical and laboratory findings got normalized including the parameters of cellular and humoral immunity.

In addition, we conducted a comprehensive symptomatic, immunomodulatory, desensitizing, detoxifying and general health-improving therapy.

As to general health-improving drugs we preferred vitamins. The patients took:

1. Berocca plus – 1t/once a day/any time/for 30 days (vitamin B 1–12, C).
2. Aevit – 1t/twice a day/while eating/for 30 days (vitamin A – E).
3. Selenium active – 1t/once a day/while eating/for 30 days (vitamin).
4. Zincteral – 1t/3 times a day/after meals/for 30 days (vitamin zinc).
5. Omega 3-6-9 fatty acids – 1t/3 times a day/while eating/for 30 days.

The diet and the regimen are very important too. It is recommended to follow the principles of rational nutrition in order to resume proper metabolism [12]. The diet should contain enough protein, fat, carbohydrates, vitamins and minerals. But animal proteins should be mainly presented by dairy products, lean meats, fish and poultry meats, and the fats with vegetable oils and butterfat. It is recommended to eliminate completely high-melting animal fats (beef, goose, mutton fats and others) replacing them with vegetable oils and butterfat.

Great importance is attached to carbohydrates as a source of constant energy. But we should only consume compound carbohydrates which are broken down gradually in the bowels and become a source of constant energy (vegetables, grains). We should exclude completely easily digestible carbohydrates (sweets and cakes). We also exclude spicy, fried, smoked and canned food – all these disturb the metabolism and irritate the skin. Alcohol and smoking are strictly prohibited [13]. A correct regimen is equally important. Demodicosis lives 24 days so you should keep your personal sterile for 30 days to avoid recurrent autoinfection [14]. Specifically:

- to change your bed linen every 3 days, to iron and to steam your pillow and its slip daily as well as other personal things;
- to use disposable wipes if towels are not available;
- to change towels after each washing.

Patients with demodicosis are not recommended to stay in the sun for a long time or use artificial methods of tanning as well as to expose their skin to wind, rain, snow, dust and other

influences which might increase its irritation and to use various thermal procedures such as baths, saunas and so on [15].

To reduce the irritant effect of the nervous system on the skin the patients are prescribed debilitants and those with sleep disorders are administered light hypnotic. For the same reason they undergo such physiotherapeutic procedures as electrosleep [16]. Moderate physical exercise and walks in the open air under the slanting sun rays (in the morning and in the evening) are also recommended.

In general, it should be noted that in the majority of patients with demodex after combined therapy despite the improvement in the general condition and relative, varying degrees of severity, regression of changes existed before treatment, takes place the full normalization of clinical and laboratory parameters characterizing the functional state of the liver indicating the resistance of these disorders.

Depending on the dynamics of both subjective and objective clinical symptoms and the results of repeated clinical and laboratory examination allowed to assess the nature and direction of development of the changes existed before treatment we adopted the following scale assessing the efficiency of complex treatment of patients with demodex [17]:

1) degree of effectiveness (complete recovery) was characterized by the disappearance of the subjective and objective clinical and laboratory signs of disease, the reverse development of changes observed before treatment;

2) degree (improvement) was characterized by the disappearance of the subjective and objective evidence of a significant reduction characteristic of demodectic mange in the acute phase, with a distinct tendency to regression of clinical and laboratory violations observed before treatment;

3) degree (no change) was characterized by a decrease of subjective symptoms at the absence of significant changes indicating regression of clinical and laboratory abnormalities existed before treatment;

4) degree (deterioration) was determined in patients with small subjective improvement or no deterioration of objective indicators testifying about the rise of pathological changes in the liver.

Comparative evaluation of reverse development of clinical symptoms after 2–5 months after treatment showed (Fig. 1, 2) that the absence or reduction of complaints is not always accompanied with an improvement of objective clinical parameters.

The amelioration was characterized by positive dynamics in the general condition of the patient, a significant regression of clinical symptoms and a reduction of objective signs of the disease, improvement of hematological parameters while maintaining positive immunological tests.

A reliable rapid regression of clinical symptoms in most patients with demodicosis justifies the advisability of administering these drugs and points out the positive effects of their use.

After complex therapy there were observed different degrees of regression of changes existed treatment. The lack of clinical response on therapy may be due to the already established treatment pathology HPDZ [18]. This is confirmed by the growth of pathological changes in clinical and laboratory parameters that caused an increase of demodicosis mange duration.

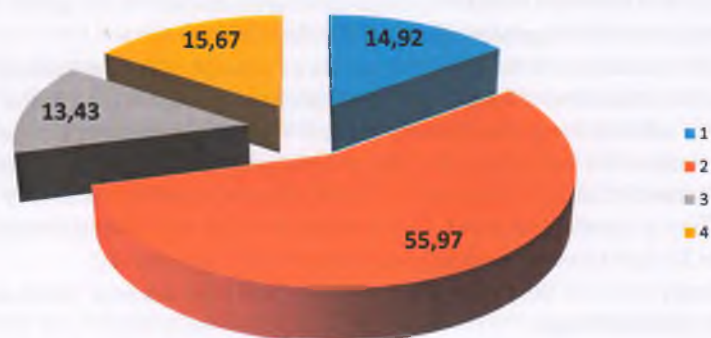


Fig. 1. The nature and frequency (%) of change of subjective clinical symptoms in demodicosis patients 2–5 months after the combined therapy: 1 – normalization; 2 – improving; 3 – unchanged; 4 – deterioration

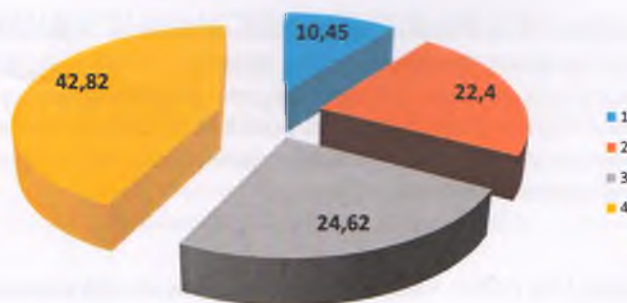


Fig. 2. The nature and frequency (%) of changes in objective clinical symptoms in patients with demodex in 2–5 months after the complex therapy: 1 – normalization; 2 – improving; 3 – unchanged; 4 – deterioration

4. Discussions

The variety and number of means of the specific combined therapy did not only suggest achieving parasitological effect. In order to find possible ways of accelerating the recovery of long flowing disturbances in the immunity patients were prescribed a hepatoprotector “Hepadif” along with anti-parasitic and conventional pathogenic treatment. This is a combined medication which pharmacological effects is the result of complex action of its components. It stimulates the metabolism of fats – components of β -oxidative conversion of free fatty acids in the mitochondria of hepatocytes, biosynthesis processes, prevents necrosis of hepatocytes, normalizes processes of proliferation of hepatocytes, liver enzyme system and helps to restore normal liver function.

As demodicosis occurs at lower immunity we made its correction and recovery of correct metabolic processes and protective properties of the skin. The action of the immune system as response on aggression of Demodex mite remains largely unexplored (as in most of other parasitic diseases). We can assume that living activities of the immune system restrains the parasite reproduction and its presence in the body in small quantities which does not lead to the development of clinical disease. In case of increasing the number of agents (due to some reasons) the immune system begins to respond more actively starting the mechanisms of inflammatory reactions.

Delayed-type hypersensitivity (DTH) reactions play a primary role in antiparasitic immune processes. At demodicosis for example it is proved that the expansion of demodectic nidus causes a severe infiltration of its external wall by eosinophils, neutrophils, histiocytes and by the cells of lymphocytic series. And phagocytes accumulated around the parasite affect it with the enzymes of their lysosomes secreting them the surrounding medium of the mite [19]. The phagocytes may even be lysed releasing all their enzymes. It may result in developing a typical inflammatory response which kills the parasite. Due to this reaction a granuloma surrounded by inflammatory cell barrier develops around the demodectic nidus. This barrier separates the host organism from the demodectic nidus and prevents penetration of toxic metabolic products of the parasite beyond its borders. That is why our patients were administered immunomodulating drugs such as immunofan intramuscularly 1 per day/for 10 days/(injections for immunity) or Cyclopheron intramuscularly 1 per day/for 10 days/(injections for immunity).

Depending on the evolution of a complex of subjective and objective clinical symptoms and on the results of the repeated clinical-instrumental examination allowing to assess the nature and direction of the changes that there were before the treatment we have adopted the following rating scale to assess the degree of efficiency of complex treatment of demodicosis.

The treatment was assessed as effective (recovery) with the normalization of the general condition of the patient, the disappearance of clinical symptoms of the disease, primarily of cutaneous manifestations, of objective evidence of the disease, with normalization of hematological and immunological tests which indicate the reverse development of changes observed before the treatment.

5. Conclusions

Thus when the treatment of demodicosis is timely and of high quality with taking into account individual choice, the correct dosage of a drug, with the selection and adherence to the

proper methods the high clinical efficiency can be achieved that is an important lever in the overall complex of public health measures against parasitic diseases.

We substantiated and developed the correction principles for disadaptation disorders at liver lesions, proposed new ways to enhance adaptive capacities of the organism and effectiveness of treatment of demodicosis based on the application of albendazole in the complex treatment with hepatoprotectors and immunomodulating therapy.

References

- [1] Del Rosso, J. Q. (2004). Medical treatment of rosacea with emphasis on topical therapies. *Expert Opinion on Pharmacotherapy*, 5 (1), 5–13. doi: 10.1517/eoph.5.1.5.25509
- [2] Cohen, A. F., Tiemstra, J. D., Board, Am. J. (2002). Diagnosis and treatment of rosacea. *Fam. Pract.*, 15 (3), 214–217.
- [3] Del Rosso, J. Q. (2005). Adjunctive skin care in the management of rosacea: cleansers, moisturizers, and photoprotectants. *Cutis*, 75 (3), 17–21.
- [4] Beridze, L. R., Katsitadze, A. G., Katsitadze, T. G. (2009). Cryotherapy in treatment of skin demodecosis. *Georgian Med News*, 170, 43–45.
- [5] Del Rosso, J. Q. (2000). Systemic therapy for rosacea: focus on oral antibiotic therapy and safety. *Cutis*, 66 (4), 7–13.
- [6] Mancini, G., Carbonare, A. O., Haremans, J. F. (1965). Immunochemical quantitation of antigens by single radial diffusion. *Immunochemistry*, 2 (3), 235–238. doi: 10.1016/0161-5890(65)90004-0
- [7] Carlotti, D. N. (1994). Therapy of generalized demodecosis with milbemycin. *Proceedings 1st European congress*, 147–149.
- [8] Nally, J. B., Berson, D. S. (2006). Topical therapies for rosacea. *J. Drugs Dermatol*, 5 (1), 23–26.
- [9] Del Rosso, J. Q. (2006). Update on rosacea pathogenesis and correlation with medical therapeutic agents. *Cutis*, 78 (2), 97–100.
- [10] Fernandez-Obregon, A. (2004). Oral use of azithromycin for the treatment of acne rosacea. *Archives of Dermatology*, 140 (4), 489–490. doi: 10.1001/archderm.140.4.489
- [11] Ljubojeviae, S., Basta-Juzbasiae, J., Lipozeneiae, A. (2002). Steroid dermatitis resembling rosacea, aetiopathogenesis and treatment. *Journal of the European Academy of Dermatology and Venereology*, 16 (2), 121–126. doi: 10.1046/j.1468-3083.2002.00388_2.x
- [12] Larson, A. A., Goldman, M. P. (2007). Recalcitrant rosacea successfully treated with multiplexed pulsed dye laser. *J Drugs Dermatol*, 6, 843–845.
- [13] Zhaxylykova, R., Lukyanets, V. (2012). The pandemic of primary chronic nonregistered disease as the main reason for increasing morbidity by «noninfection» illnesses in people in the beginning of XXI century. *Euromedica Hannover*, 236–237.
- [14] Yoo, J., Reid, D. C., Kimball, A. B. (2006). Metronidazole in the treatment of rosacea: do formulation dosing and concentration matter? *J. Drugs dermatol.*, 5, 317–319.
- [15] Melnick, S. (2005). Cystic acne improved by photodynamic therapy with short-contact 5-aminolevulinic acid and sequential combination of intense pulsed light and blue light activation. *J Drugs Dermatol*, 4 (6), 742–745.
- [16] Tzung, T. Y., Wu, K. H., Huang, M. L. (2004). Blue light phototherapy in the treatment of acne. *Photodermatology, Photoimmunology and Photomedicine*, 20 (5), 266–269. doi: 10.1111/j.1600-0781.2004.00109.x
- [17] Van Zuuren, E. J., Gupta, A. K., Gover, M. D., Graber, M., Hollis, S. (2007). Systemic review of rosacea treatments. *Journal of the American Academy of Dermatology*, 56 (1), 107–115. doi: 10.1016/j.jaad.2006.04.084
- [18] Van Vloten, W. A., van Haselen, C. W., van Zuuren, E. J., et al. (2002). The effect of two combined oral contraceptives containing either drospirenone or cyproterone acetate on acne and seborrhea. *Cutis*, 69 (Suppl. 4), 2–15.
- [19] Oberemok, S. S., Shalita, A. R. (2002). Acne vulgaris. I. Pathogenesis and diagnosis. *Cutis.*, 70, 101–105.
- [20] Lehmann, P. (2005). Rosazea Klinik, Pathogenese, Therapie. *Der Hautarzt*, 56 (9), 871–887. doi: 10.1007/s00105-005-1009-3